



## Case Report

# PANDEMIC IMPACT COVID-19 ENCOURAGING A MOTHER KILLING HIS CHILDREN

**Asan Petrus**, Department of Forensics and Medicolegal  
Faculty of Medicine, University of North Sumatra, Medan

### Article Info

#### \*Corresponding Author:

Asan Petrus

Email: [asanpetrus95@gmail.com](mailto:asanpetrus95@gmail.com)

### Abstract

**Background;** In the early 2020s, the world, especially Indonesia, was shocked by the spread of a new virus, a new type of coronavirus (SARS-CoV-2) and a disease called coronavirus disease 2019 (COVID-19) which had claimed more than 90,000 people and not only affected the life threat. infected with the virus but also against the threat of life due to hunger. The people not only lost their jobs because the company had to stop while also traders and traditional markets had to close because there were found traders who were positive co-19.

**Case;** A case was reported with the victim of a girl with the initials NS, age 1.8 years old. The victim was taken to the Medan HAM Hospital by the police together with a request from Visum et Repertum and a body examination and body surgery were performed at that time.

**Results;** on external examination found both lips and fingertips in blue and smelled of baygon from the mouth of the victim of the examination found bleeding spots (tardeus sport) on the surface of the lungs and on the surface of the heart, the contents of the stomach containing food scraps that smell like stimulating baygon. POLDASU forensic laboratory results; Baygon (+)

**Discussion:** based on the history of the investigator who went to the scene of the crime the suspect was the victim's mother who has been arrested and is currently undergoing treatment in the hospital due to baygon poisoning. She was taken alone after poisoning her child (victim).

**Conclusion;** a victim of a girl's dead body, known, 82 cm long, moderate stature, brown skin, and straight black hair that is difficult to pull out. From the results of external and internal examination as well as POLDASU Medan forensic laboratory examination, the victim died from baygon poisoning.

**Keywords:** covid-19, baygon poisoning.

**Preliminary:**

In early 2020, the world was shocked by the spread of a new virus, a new type of coronavirus (SARS-CoV-2) and a disease called coronavirus disease 2019 (COVID-19) (Yuliana, 2020). Coronavirus is a group of viruses that can cause disease in animals or humans. Coughs from colds to more serious ones such as Middle East Respiratory Syndrome (MERS) and Severe Acute Respiratory Syndrome (SARS). A new type of Coronavirus has been found to cause COVID-19. COVID-19 is an infectious disease caused by a newly discovered type of coronavirus. before the outbreak in Wuhan, China, in December 2019 (WHO, 2020).

On March 2, the President of the Republic of Indonesia, Joko Widodo announced two residents of Depok, West Java, were positively infected with COVID-19. The two cases were then referred to as case 01 and case 02. Case 01 was female (31), direct contact with a Japanese citizen who turned out to be the 24th positive case in Malaysia. Case 02 was a woman (64) who had direct contact with case 01. She was the mother of patient 01 and lived in the same house (CNNI, 2020).

Until now it has claimed more than 90,000 people and is still showing a significant increase in cases. This co-19 pandemic not only affects the life threat due to being infected with the virus but also the life threat from hunger. Many Indonesian people who not only lost their jobs because the company had to stop while also traders and traditional markets had to close because found positive traders covid-19. This condition causes a mother to act out of the ordinary, namely killing her child by giving baygon poison while the mother kills herself also with the baygon liquid, but does not die and must undergo treatment in the hospital ..

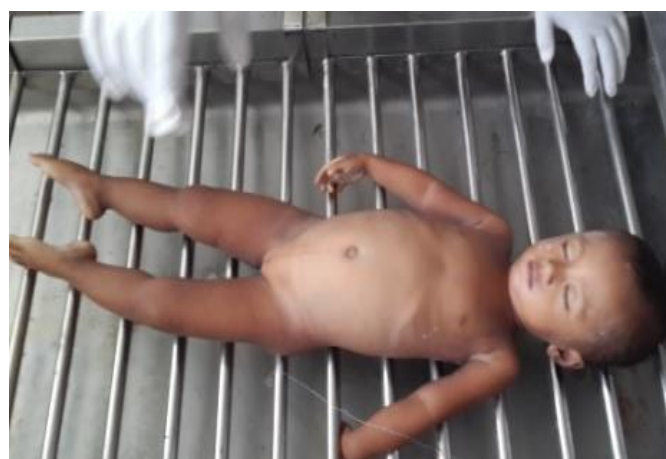**Case Report:**

A case was reported with the victim of a girl with the initials NS, age 1.8 years old, the victim was taken to Medan HAM Hospital by the police together with a request from Visum et Repertum and a body examination and body surgery on that same day.

Inspection Findings

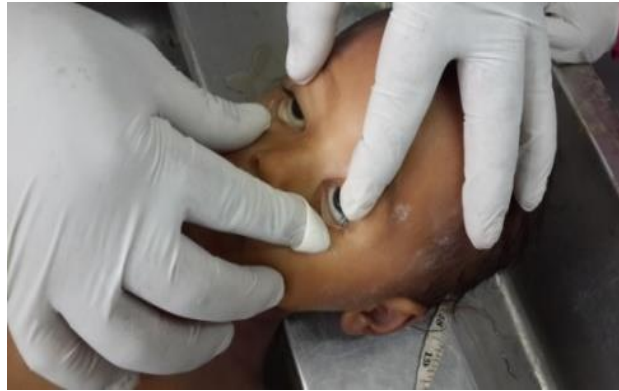**I. General Inspection**

We found a corpse of children, women, known, 82 cm long, medium stature, brown skin color, and black hair, straight, difficult to pull out. There was a bruising of the corpse on the back of the neck, back, and waist that did not disappear on emphasis. Rigid corpse not found, Rotting found in green on the lower abdomen left and right, the skin on the back is easy to peel.

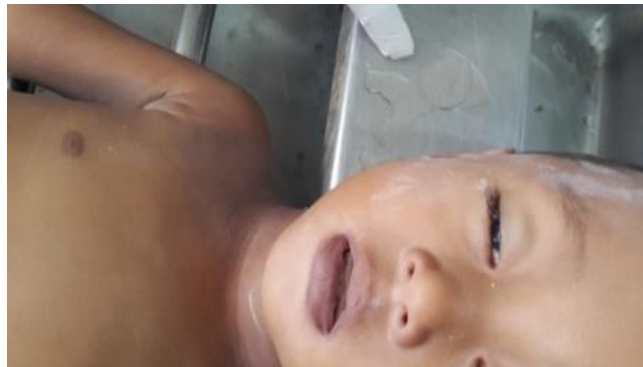

**II.Examination Outside**

Eyes: There are two pale inner eyelids, no bleeding spots



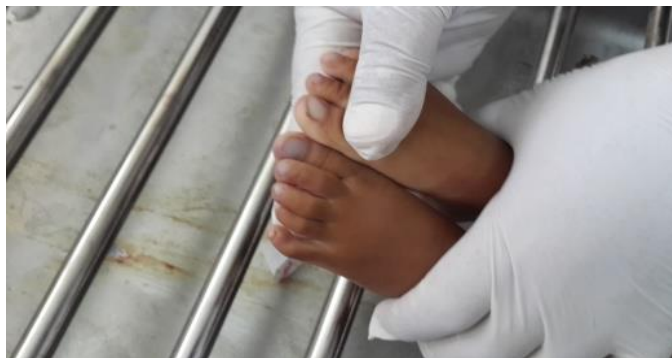Mouth: Blue lips are found, smelled like baygon



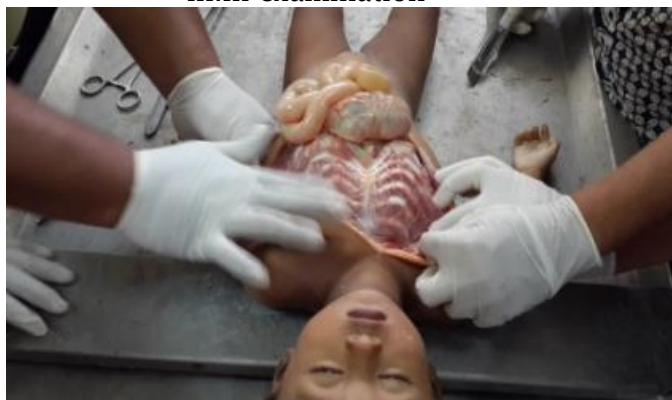Upper limbs: Found blue fingertips, No signs of violence and broken bones were found

Lower limbs

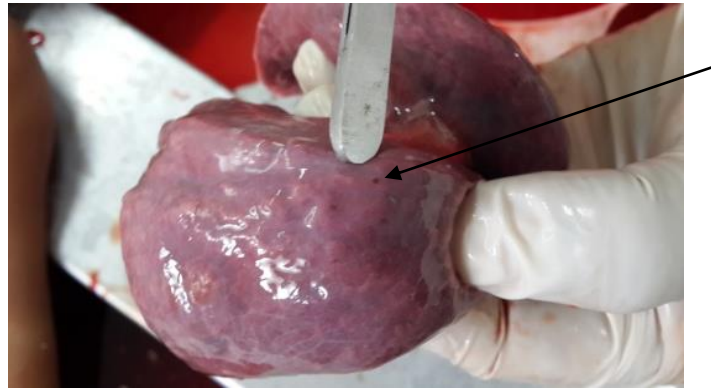
Blue fingertips found, no signs of violence and broken bones were found



### III. In-examination

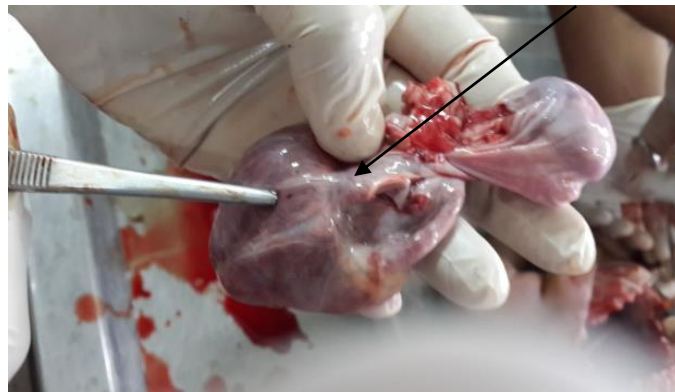

Lung: Lung reddish brown, palpable sponge, Found bleeding spots At the opening of the lower



respiratory tract visible soft foam that is difficult to break

Heart: Found brownish red heart, flat surface, felt chewy. Bleeding spots were found



Stomach: Stomach surface is pale brown.

At the opening of the stomach pouch, soft food scraps are found in the form of rice grains, green vegetable residues, and brownish-colored liquid and smell stimulating like baygon.

Additional tests: POLDASU forensic laboratory results Medan: baygon (+)

### **Discussion:**

From the examination of the victim's body it is estimated that the victim died between 12-24 hours ago based on the signs found in the form of bruised corpses that do not disappear on the emphasis and rigid corpses that have disappeared (the relaxation phase) and found the initial decay process.

From the external examination found both the lips and fingertips in blue and internal examination found spots of bleeding (tardeus sport) on the surface of the lungs and on the surface of the heart showed that before death the victim experienced a respiratory disorder (asphyxia) which then ended in death.

From the external examination, the odor of baygon from the victim's mouth was smelled, as well as an internal examination in the form of stomach contents containing leftovers that smelled like stimulating baygon. to further confirm the cause has been sent to the POLDASU criminology laboratory food waste materials in the stomach and blood for toxicological examination, and the results of the POLDASU criminology laboratory stated baygon (+). The conclusion was that the cause of death was suffocation due to baygon poisoning. Based on the interim investigation that we got from the history of the investigator who took the victim, that the victim was given baygon poison by his mother and then part of the baygon was drunk by his own mother. Based on her mother's confession it was done because her mother could not bear to see her child starve because her mother had no work at all during the Covid-19 pandemic and her husband had long since left them. So his mother

planned to die together. But it was known by his neighbor so that his mother received help and is currently being treated at the hospital.

**Conclusion:**

a victim of a girl's dead body, known, 82 cm long, moderate stature, brown skin, and straight black hair that is difficult to pull out. From the results of external and internal examination as well as POLDASU Medan forensic laboratory examination, the victim died from baygon poisoning. As a victim of a murder committed by his own mother, triggered by economic difficulties due to the prolonged Covid-19 pandemic.

**Legal aspects**

The perpetrator in this case is his own mother, so the criminal sanctions imposed on the perpetrators are Republic of Indonesia Law No.23 of 2004 concerning the elimination of domestic violence, in this law the victim violates Article 44 (4) in the case of the acts referred to in Paragraph (2) results in the death of the victim, sentenced to a maximum imprisonment of 15 (fifteen) years or a maximum fine of Rp. 45,000,000.00 (forty-five million rupiah).

**Bibliography:**

- [1.] Wang, W. Tang, J., Wei, F. 2020. Updated understanding of the outbreak of 2019 novel coronavirus (2019-nCoV) in Wuhan, China. J Med Virol. 92:441-447 WHO, 2020. Coronavirus disease 2019 (COVID-19) Situation report-81.
- [2.] [https://www.who.int/docs/default-source/coronaviruse/situation-reports/20200410-sitrep-81-covid-19.pdf?sfvrsn=ca96eb84\\_2](https://www.who.int/docs/default-source/coronaviruse/situation-reports/20200410-sitrep-81-covid-19.pdf?sfvrsn=ca96eb84_2)
- [3.] Yuliana. 2020. Corona virus diseases (COVID-19): sebuah tinjauan literatur. Wellness and healthy magazine. vol.2, no.1, hal. 187-192.
- [4.] Sjamsuir Munaf, keracunan akut pestisida, cetakan I, Widia Medika, Jakarta, 1997, Hal.1-10,23
- [5.] Shahrom Abd.wahid, Patologi Forensik, cetakan pertama, Dewan Bahasa dan Pustaka, Selangor Darul Ehsan, 1993 hal. 452-3.
- [6.] Gani MH. Ilmu kedokteran Forensik. Bagian Kedokteran Forensik Fakultas Kedokteran Universitas Andalas, Padang, 2002, hal.149-150.
- [7.] Chadha PV, Ilmu Forensik dan Toksikologi, Hand Book of Forensic Medicine And Toxicologi, edisi V, Widya Medica, Jakarta, 1995: 256-257.
- [8.] Budiyanto A, Widiatmaka W, Sudiono S, dkk, Ilmu Kedokteran Forensik .Bagian Kedokteran Forensik FKUI Jakarta, edisi pertama, 1994 Hal. 26-28.
- [9.] Undang-undang Republik Indonesia no.23 tahun 2004 tentang penghapusan kekerasan dalam rumah tangga. file:///C:/Users/User/Downloads/IDN91238%20IDN%20(1).pdf unduh tanggal 20 Juli 2020