

## SPIGELIAN HERNIA IN THE LEFT ABDOMINAL WALL

Amine Hermi , Imen Ben Ismail, Sabeur Rebi, Hakim Zenaidi and Ayoub Zoghalmi

University of Tunis El Manar, Department of general surgery, Trauma center Ben Arous, Tunisia

### Article Info

#### \*Corresponding Author:

Amine Hermi

Email: hermiamine@gmail.com

### Abstract

Spigelian hernia is a rare variety of abdominal wall defects appearing between the large abdominal muscles lateral to the rectus abdominis through Spigelian aponeurosis. Its diagnosis is challenging. The risk of incarceration is high, which urge surgical treatment. However, the risk of recurrence is low.

We report the case of a female patient with a palpable abdominal mass in the left abdominal wall, Spigelian hernia was diagnosed by computed tomography (CT). Open surgery was performed. The defect was closed by a polypropylene mesh. The patient had a favorable outcome for 1 year without recurrence.

**Keywords:** Spiegel, Hernia, surgery

### Introduction:

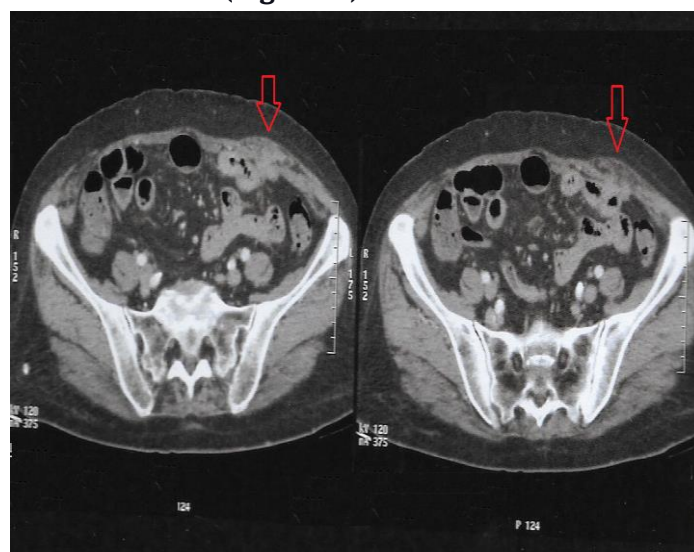
Spigelian hernia is very rare, accounting approximatively for less than 2 % of all abdominal wall hernia. Because of its rarity and the difficulty of detecting early symptoms, the diagnosis of this entity is often delayed, which arises the rate of hernial incarceration. Surgery is the only treatment to offer, with usually good results.

### Observation:

A 75-year-old woman consulted for a palpable mass in the left abdominal wall that appeared two months prior. The patient has an extensive medical history, including asthma, coronary stents, thrombophlebitis in the left leg for which Acenocoumarol has been prescribed for six months, cholecystectomy, and appendectomy.

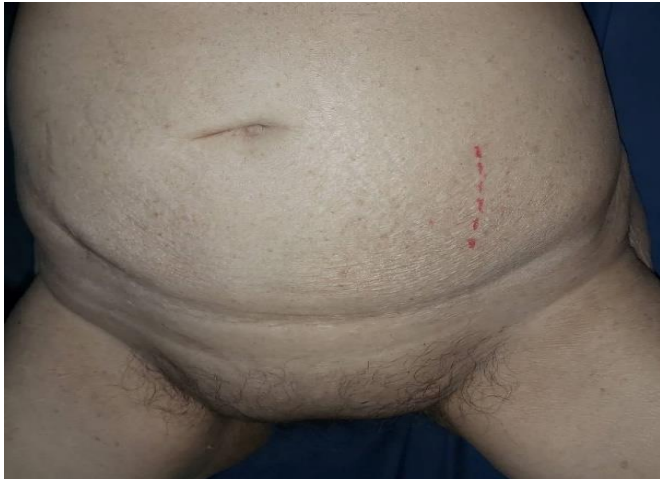Clinical examination showed a palpable mass measuring about 5 cm, located in the left abdominal wall. It was painless and utterly reducible with an expansile cough impulse.

An abdominal computed tomography was performed and showed a herniation of omentum through the fascial defect of the left lower abdominal wall (**Figure 1**).



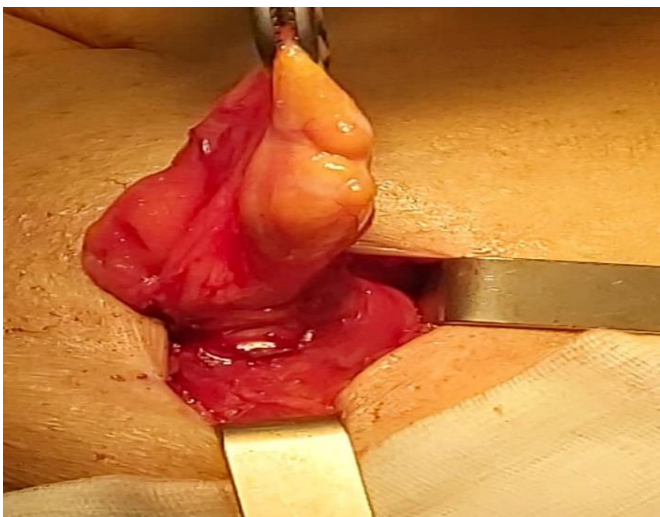
**Figure 1:** Abdominal CT depicting a Spigelian hernia (arrow).

The diagnosis of uncomplicated Spigelian hernia was made. The patient underwent open surgery after 24 hours. A 4 cm paramedian incision was made on the left lower quadrant over the palpable mass (**Figure 2**). The external oblique aponeurosis is incised, and the sac is located and dissected from all surrounding tissues until the hernia orifice is reached.



**Figure 2:** Paramedian incision over the palpable mass

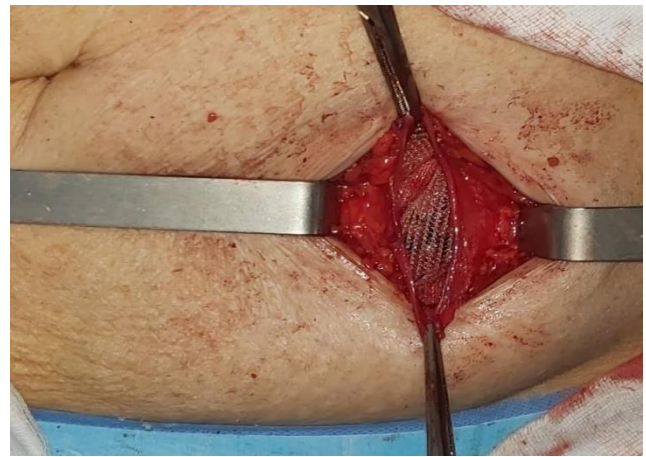
The hernia sac was identified and opened after circumferential dissection. Omentum with no ischemic changes was found incarcerated (**Figure 3**). It was easily reduced into the abdominal cavity revealing a 3 cm fascial defect.



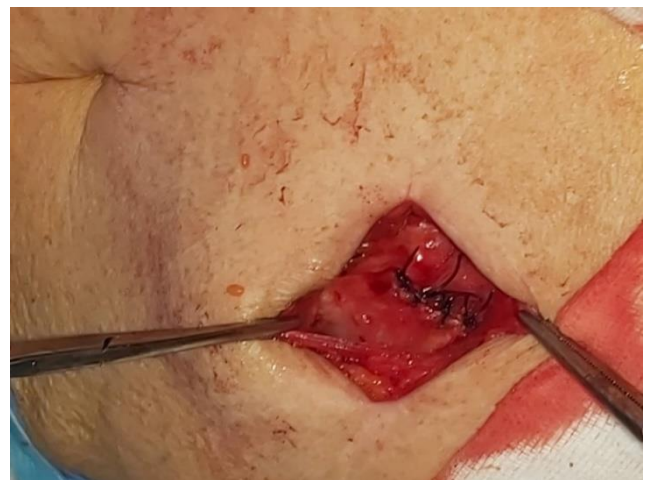**Figure 3:** Intraoperative findings: identification of the hernia sac

and omentum in a Spigelian hernia.

The defect was repaired with a prosthetic self-expanding polypropylene mesh that was anchored to the orifice with interrupted sutures. The wound was closed (**Figure 4,5**).



**Figure 4:** Repair of the defect by a polypropylene mesh



**Figure 5:** Separate sutures after putting the mesh

The postoperative recovery was uneventful, and the patient tolerated a regular diet on postoperative day 2 and was discharged on oral analgesics.

#### **Discussion:**

Spigelian hernia constitutes 0,12% to 2% [1] of abdominal wall hernias. Its diagnosis is more challenging than its treatment. It frequently goes unrecognized and underreported. However, the incidence of this entity has been increasing because it is more easily recognized by modern imaging. It can be congenital or acquired [2].

A Spigelian hernia can occur at any point along the semilunar line: It is the line forming and making the transition from muscle to aponeurosis in the transversus abdominis muscle [3].

It can occur at any age, usually in the sixth decade, affecting both sexes equally [4].

Classic hernia predisposing factors are described in Spigelian hernia: Morbid obesity, multiple pregnancies, prostatic enlargement with dysuria, pulmonary diseases with chronic cough, rapid weight loss in obese patients and history of open abdominal surgery [2].

In most cases, the Spigelian hernia sac harbors omentum, small bowel, appendix, or coecum [5].

The hernial orifice is 0,5 to 20 mm in diameter [3].

With such small orifice size, the Spigelian hernia can be difficult to detect in obese patients, and the risk of strangulation is important (20-30%) [3].

The symptoms are usually pain, a palpable mass in the anterior wall, and signs of incarceration with or without intestinal obstruction.

Imaging is recommended. Ultrasonic scanning and mainly computed tomography are very accurate in offering detailed information on the hernial orifice, the sac, and the sac content [5].

A Spigelian hernia should be treated surgically. This operation is usually simple to perform. The paramedian incision usually gives a good exposure and enables the surgeon to inspect a large part of the Spigelian aponeurosis without cutting muscles and ventral aponeurosis. Laparoscopic management of this rare condition has been described with intra- and extraperitoneal

techniques with good results when performed electively [6].

### **Conclusion:**

Spigelian hernia is a rare entity that is underdiagnosed. Modern imaging is recommended to establish the right diagnosis. The surgical treatment should not be delayed because of the high risk of incarceration of this variety of hernias.

### **References:**

- [1.] Balthazar EJ, Subramanyam BR, Megibow A. Spigelian hernia: CT and ultrasonography diagnosis. *Gastrointest Radiol.* 1984;9(1):81-4.
- [2.] Richards AT. Spigelian hernias. *Oper Tech Gen Surg.* sept 2004;6:228-39.
- [3.] Spangen L. Spigelian Hernia. *Surg Clin North Am.* 1 avr 1984;64(2):351-66.
- [4.] Wiedeman JE, Clay J. The open mesh repair of Spigelian hernia. *Am J Surg.* sept 2008;196(3):460-1.
- [5.] Marschall J, Vergis A. Radiology for the surgeon. *Can J Surg.* avr 2004;47(2):119-20.
- [6.] Moreno-Egea A, Carrasco L, Girela E, Martín J-G, Aguayo JL, Canteras M. Open vs laparoscopic repair of spigelian hernia: a prospective randomized trial. *Arch Surg Chic Ill* 1960. nov 2002;137(11):1266-8.