

OSTEOSARCOMA OF RADIAL DIAPHYSIS: A PEDIATRIC CASE REPORT.

A. Elbahraouy[★]; T. Elyaakoubi; A. Zaizi; B. Chafry; S. Bouabid; M. Boussouga

Department of Traumatologic-Orthopédic, Military Hospital Mohamed V, Rabat, Morocco

Article Info

*Corresponding Author:

Dr Abdellatif Elbahraouy

Email: abdellatifelbahraouy1@gmail.com

Abstract

Osteosarcoma is the most common primary malignant bone tumor in children. It can affect all bones but has a predilection for the metaphyses of the long bones and appears in the knee in most cases. Osteosarcoma is rare in the forearm and the radius of her right arm. We report the case of a 13-year-old girl with osteosarcoma of the middle third of the radius. A thoraco-abdominopelvic scanner and bone scintigraphy were performed as part of the extension work-up and did not indicate metastasis. Following neoadjuvant chemotherapy, surgery consisted of an oncological resection of the tumor with the removal of more than two-thirds of the proximal radius, followed by an ulnarization of the forearm six months after the failure of distal radioulnar arthrodesis. After surgery, the patient received adjuvant chemotherapy. The clinical and functional outcomes were satisfactory at the five-year follow-up evaluation.

Keywords: Osteosarcoma, radius, polychemotherapy, ulnarization of the forearm.

Introduction:

Osteosarcoma is the most common primary malignant bone tumor in children [1]. It mostly affects boys with a peak frequency between age 10 to 20 years. The radial diaphyseal location of osteosarcoma is a rare anatomical entity [2]. Survival has been improved through early diagnosis and polychemotherapy.

Polychemotherapy induces tumor reduction, which makes the preservation of the limb possible via conservative surgical techniques and ensures a satisfactory resection of the tumor. This approach yields survival rates of nearly 70% to five years [3]. Before the introduction of polychemotherapy, >90% of patients with

osteosarcoma died from pulmonary metastases [4].

Case report:

A 13-year-old girl without medical or surgical antecedents nor any personal or family history of malignancy or traumatism presented with concerns of right forearm pain lasting six months. On clinical examination, we noted a swelling in the lateral face of the middle third of the forearm, superficially mobile, with no cutaneous or neurovascular compression. The clinical examination did not reveal the presence of lymphadenopathies. The patient was afebrile, and her general condition was stable.

Standard radiography of her forearm showed a lacunary osteolytic image in the middle third of the right radius (figure 1). An MRI was performed as a part of the locoregional assessment, which showed a lacunary image measuring 4 cm x 2 cm with no involvement of the soft tissue. We noted the neurovascular pedicle. (figure 2)

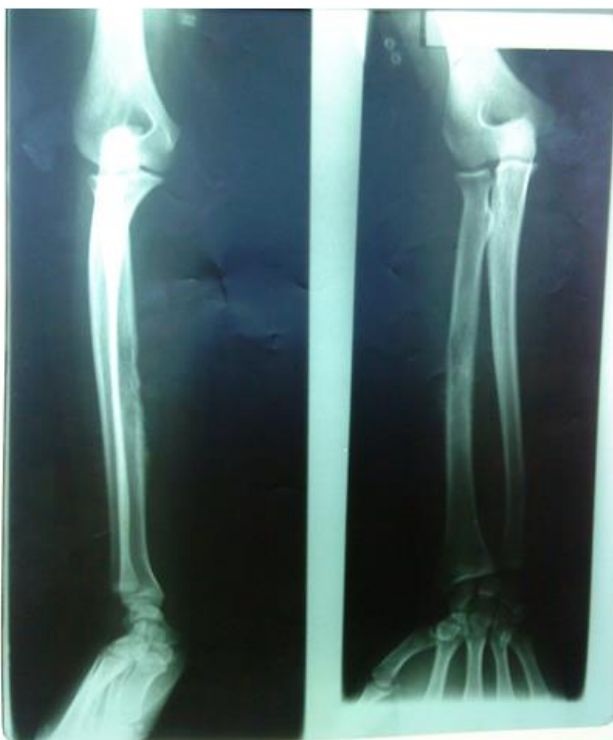

Figure 1: X-ray of the forearm showing a lacunar image of the RADIUS.

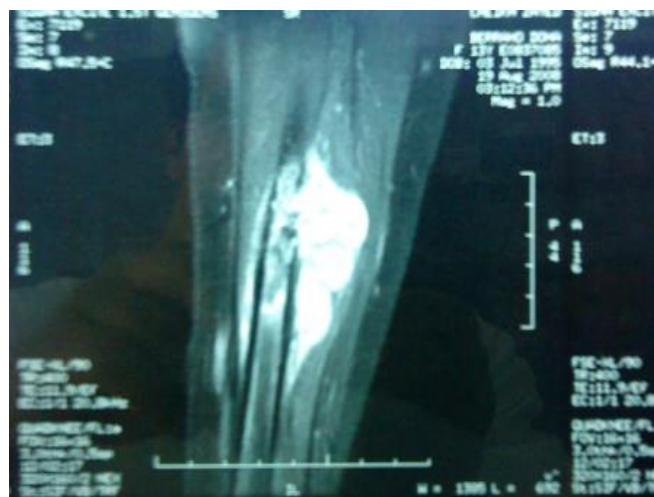

Figure 2: MRI showing a lytic image measuring 4cm/2.

A biopsy was performed using the Henry anterior approach; the histopathological examination indicated osteoblastic osteosarcoma via atypical osteoblasts, immature osteoid, irregular anastomotic network (indicating tumor osteogenesis), and osteoblastic extracellular matrix. A thoraco-abdominopelvic scanner and bone scintigraphy were performed but did not indicate metastasis.

Chemotherapy was indicated for the patient. The therapeutic protocol adopted at the Center for Pediatric Hematology and Oncology, Children's Hospital, Rabat University Hospital, Morocco: three cycles of chemotherapy 21 days apart (adriamycin, 25 mg/m² days one, two, and three; cisplatin 100 mg/m² day one) and surgery scheduled for day 21 of the third cycle of chemotherapy.

We opted for a conservative surgical treatment for the patient according to the Henry anterior approach, which consisted in removal of the entire tumor up to 3cm from the wrist joint, including part of the pronator teres muscle with more than two-thirds of the proximal radius (figure 3) followed by distal radioulnar arthrodesis with a screw and pin to obtain a

functional wrist (figure 4). Six months after failure of the arthrodesis, an ulnarization of the radius by a screwed plate was performed (figure 5).

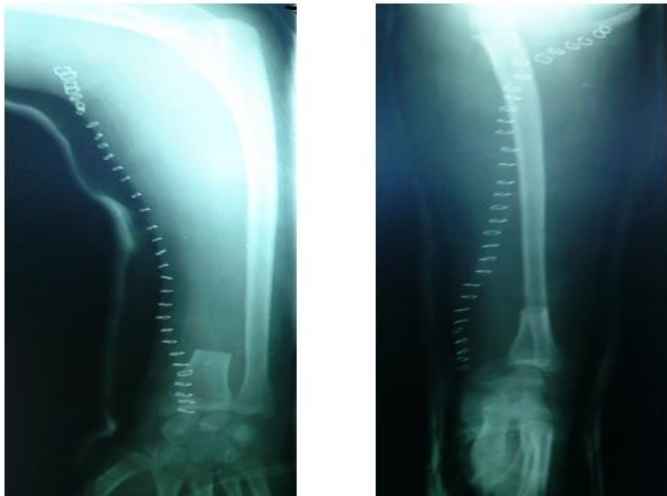


Figure 3: post-operative control after the resection of the 2/3 proximal RADIUS.

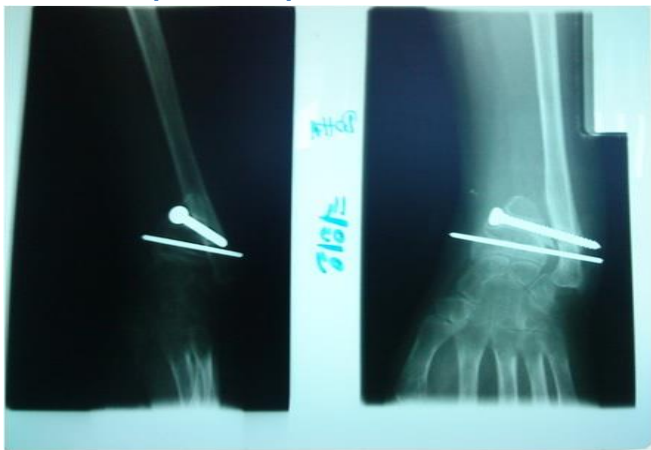


Figure 4: X-ray of the forearm F + P showing the failure of the distal radio-ulnar arthrodesis

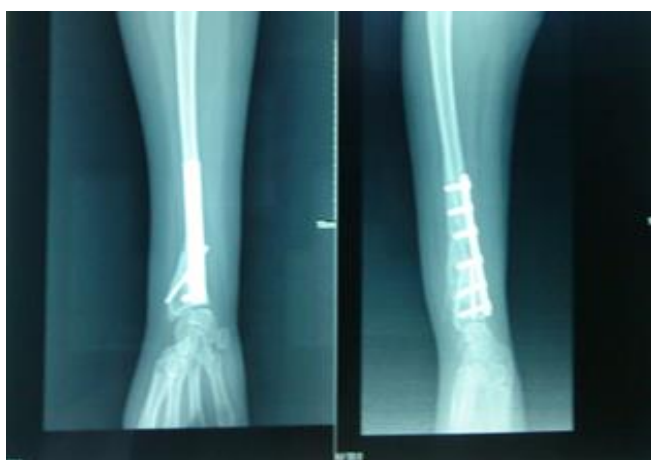

Figure 5: post-operative control after ulnarisation of the RADIUS.

The definitive anatomopathological study of the operative part confirmed the diagnosis of osteosarcoma with good tumor response to chemotherapy, including an 80% tumor necrosis rate.

The patient received three additional rounds of postoperative chemotherapy identical to the first three rounds, for a total of six treatments. Five years postoperatively, the patient had no signs of local recurrence or metastasis. Functionally, the results were satisfactory with good articular amplitudes, and the patient maintains a normal family and school life. (figure 6).

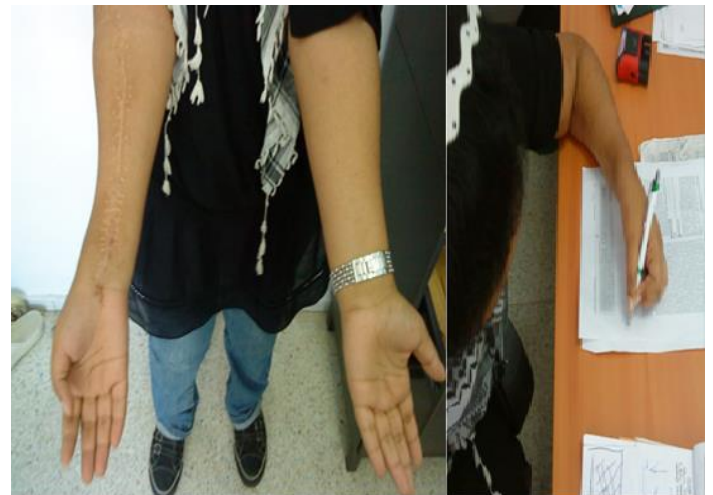

Figure 6: Clinical functional outcome four months after the last surgery.

Discussion:

Malignant bone tumors are rare in children, representing only 5% of all pediatric tumors. Malignant bone tumors are often primitive and dominated by intramedullary osteosarcoma. It mostly affects boys during the second and third decades of life and is usually present in the metaphyses of the long bones. The knee is the most common location, followed by the lower extremity of the femur in 40% of cases, the upper end of the tibia in 15% of cases, then the upper extremity of the femur and the humerus in 14% of cases [1]. Osteosarcoma in the upper limb is rare;

osteosarcoma of the forearm is exceptionally rare [2].

Osteosarcoma first presents in 95% of cases as permanent or intermittent pain localized to the tumoral zone or projected area. The associated pain is often improved by early rest and is misleading—it may persist for several weeks or months. Therefore, physicians should bear in mind that a child's unexplained bone pain must be explored. Signs such as general state deterioration and fever are rare and suggest the presence of metastases.

X-rays most often show signs of a very aggressive tumor with periosteal appositions, destruction of the cortex, and invasion of the soft tissues. The tumor may be purely lytic, purely condensing, or, most often, mixed, associating bone lysis and condensation. MRI is the choice exam for analyzing the local extension of a tumor.

Surgical biopsy is the most crucial step in management and is governed by many specific rules. Whenever possible, the biopsy should be performed after the MRI so as not to create an artifact through hematoma or edema. The extended work-up assessment includes a chest scanner and bone scintigraphy. The location of these metastases is pulmonary in 90% of cases and the bone in 10% of cases [5,6].

The combination of induction chemotherapy, surgery, and adjuvant chemotherapy is the usual regimen and has transformed the prognosis of this pathology. Preoperative chemotherapy is commonly administered to eradicate micro-metastases and prepare for conservative surgery. Currently, preservation of the limb is possible for most patients, and survival without any recurrence is around 50% to 80%, depending on the series [7,8].

The reconstruction of the single-bone forearm by ulnarizing the lower end of the radius allows for the creation of a solid and functional forearm via much simpler means than microsurgical reconstruction. The series reported in the literature are few, and therapeutic indications are varied [9]. Ulnarization was described by Hey-Groves who had rebuilt a forearm following traumatic loss of bone tissue, and the technique was further developed by Greenwood in 1932 in a child whose radius had been destroyed by osteomyelitis [10,11]. Watson-Jones reported his experience in 1934 when treating osteomyelitis with diaphysectomy using the original Hey-Groves technique [12].

Conclusion:

This report describes a rare case of osteosarcoma in the forearm of a young girl who was successfully treated with surgery, polychemotherapy, and ulnarization of the radius. The current treatment of osteosarcomas requires a multidisciplinary team with actors at all diagnostic and therapeutic stages including radiologists, anatomopathologists, chemotherapists, surgeons, and psychologists. A multidisciplinary approach allows patients to benefit from a tailored treatment offering the best chance of healing with the best possible functional results

References :

1. Guinebretière JM, Le Cesne A, Le Pécoux C: Ostéosarcome de forme commune. *Ency Med Chir.* 2001, 2: 14-704. URL: <https://www.em-consulte.com/article/8309/osteosarcome-de-forme-commune>
2. Anract P, Tomeno B: Résection-reconstruction de l'os du membre supérieur. *EMC Rhumatologie-*

- orthopédie. . 2005, 2: 355-375. <https://doi.org/10.1016/j.emcrho.2005.04.002>
3. Berard PM, Chotel F: Ostéosarcome chez l'enfant, oncologie pédiatrique . 2006, 8: 546-550.
URL : <https://link.springer.com/article/10.1007/s10269-006-0453-8>
4. Fletcher CD, Unni KK, Mertens F: Pathologie et génétique des tumeurs des tissus mous et des os. 546-550 . Presse du CIRC, Lyon, France; 2002.
https://books.google.fr/books?hl=fr&lr=&id=dg9am0g4EP8C&oi=fnd&pg=PA3&dq=Fletcher+CDM,+Unni+KK.+MertensF:+Pathology+and+genetics+of+tumours+of+soft+tissue+and+bone&ots=zuwgQHgps_&sig=_YBo2SFGb_YPexKt9exfPgje9Ug#v=onepage&q=Fletcher%20CDM%20C%20Unni%20KK.%20MertensF%3A%20Pathology%20and%20genetics%20of%20tumours%20of%20soft%20tissue%20and%20bone&f=false
5. Mialou V, Philip T, Pérol D: Ostéosarcome métastatique: facteurs pronostiques et traitement. bulletin du cancer Volume 88, numéro 11, Novembre 2001
URL :
https://www.jle.com/fr/revues/bdc/e-docs/les_osteosarcomes_metastatiques_facteurs_pronostiques_et_traitements_70336/article.phtml
6. d'Andon A, Vassal PG, Oberlin O, Hartmann O: Les tumeurs osseuses. Villejuif: Institut Gustave Roussy. 2004.
URL:
<http://www.donationlousalome.org/IMG/pdf/TUMOSGP.pdf>
7. Kalifa C, Brugières L: Traitement néoadjuvant des ostéosarcomes . Bulletin du Cancer. . 2006, 93: 1115-20.
DOI : 10.1684/bdc.2006.0164
8. Brugières L, Piperno-Neumann S: La chimiothérapie des ostéosarcomes . Oncologie. 2006, 9: 164 - 169.
URL:
<https://link.springer.com/article/10.1007/s10269-006-0576-y>.
9. Bessy H, Leemrijse T, Cadot B: Reconstruction de la perte osseuse de l'avant-bras par cubitalisation du radius (un avant-bras osseux): Commentaires sur six cas cliniques . Chirurgie de la Main. 1996, 15: 199-211. [doi.org/10.1016/S0753-9053\(96\)80027-5](https://doi.org/10.1016/S0753-9053(96)80027-5)
10. Meziani N, Yakoubi M, Nait DD: Pseudoarthrose ancienne avec grande perte de substance osseuse du radius traité avec la technique Watson-Jones: un rapport de cas . Chirurgie de la main. 2014, 33: 144. DOI: 10.1016 / j.main.2014.02.001.
- 11- Greenwood HH: Reconstruction of forearm after loss of radius; British Journal Surg. 1932,20: 58-60. doi.org/10.1002/bjs.1800207709
- 12 -Jones RW: Reconstruction de l'avant-bras après perte du radius . Br J Surg. 1934, 22: 23-26. doi.org/10.1002/bjs.1800228504