



## Original Article

# The Clinical Results of Tendon Transfers in Patients with Ulnar Palsy

Serdar Karaman<sup>1\*</sup>, Serhat Ekrem<sup>2</sup>, Kadir Ertem<sup>2</sup>

1. *Elbistan State Hospital,  
Department of Orthopedics and  
Traumatology Specialist,  
Kahramanmaraş, Turkey*

2. *İnönü University Medicine  
Faculty Department of  
Ortopedic and Traumatology,  
Malatya, Turkey.*

### Abstract

**Objective:** In this study, we aimed to evaluate the results of our preferred tendon transfer methods for deformities in 14 patients with high and low ulnar nerve palsy.

**Methods:** Between 2012 and 2018, 14 patients, 3 female and 11 male, with average follow-up of 5 (min: 2 max: 8) years, 6 low and 8 high level, average of 6.2 (min: 2 max: 20) years from injury to surgery were evaluated in the study. The last examinations and tests of the patients were performed in our clinic after their consent was obtained. The claw hand presence, Froment sign, Wartenberg sign, key pinch test, strong grip measurement, Quick Dash (QD) test, satisfaction questioning and complications were evaluated in the examinations of the patients.

**Results:** For claw hand; Zancolli lasso procedure was underwent using splits of FDS-3 in 11 patients, FDS-4 and FDS-5 in 2 patients. For the Wartenberg sign; the EDM tendon was passed through the extensor hood and A2 pulley tenodesis was performed in 13 patients. Tenodesis was performed in 12 patients using ECRB tendon for thumb adductorplasty. The EIP tendon was transferred to the 1st interosseous in 12 patients for 2nd finger abduction and improve key pinch. Tenodesis was underwent to 2nd-5th FDP's at the wrist level for the patients with high ulnar palsy. Complications such as claw hand recurrence in one, flexion contracture of the 5th finger in 1, and hyperabduction of the index finger in 2 patients were found. The strong grip and key pinch measurements were evaluated as % 62.7(max: 85 min: 22) and %63.4(max: 90 min: 33) on average compared to the opposite hand. Postop QD mean scores of the patients were evaluated as 36.8 (max: 45 min: 9.5).

**Conclusion:** When dealing with the sequelae of late ulnar nerve palsy, each patient's needs should be carefully evaluated and choosing suggested transfer methods.

**Keywords:** ulnar palsy, claw hand, tendon transfer, ulnar nerve. .

Copyright : © 2022 The Authors. Published by Publisher. This is an open access article under the CC BY-NC-ND license (<https://creativecommons.org/licenses/by-nc-nd/4.0/>).

**Supplementary information** The online version of this article (<https://doi.org/xx.xxx/xxx.xx>) contains supplementary material, which is available to autho-rized users.

**Corresponding Author:** *Serdar Karaman, Department of Orthopedics and Traumatology, Elbistan State Hospital, Kahramanmaraş, Turkey*

**Introduction:** Ulnar nerve injury impairs extrinsic and intrinsic hand movements with loss of sensation on the little finger and ulnar side of ring finger and the ulnar border of the hand. The loss of intrinsic muscles in the hand causes severe impairment of fine motor movements, including key pinch grip. The loss of flexion of small and ring finger distal interphalangeal joints (DIP) combined loss of ulnar wrist flexor impairs hand grip strength[1]. The weak key pinch caused by the loss of the first dorsal interosseous and thumb adductor is compensated by interphalangeal(IP) joint flexion (flexor pollicis longus [FPL]) and adduction (extensor pollicis longus [EPL]) which is called the Froment's sign [2]. The claw hand causes hyperextension of these joints and flexion of the IP joints by long flexors due to the unregulated movement of the extensor digitorum communis (EDC) on the metacarpophalangeal(MCP) joints. Normally, the intrinsic muscles will cross the MCP joint and lengthen the IP joints[3]. Musculotendinous units affected by low ulnar nerve palsy are: adductor pollicis, deep head of flexor pollicis brevis (FPB), dorsal and palmar interosseous, abductor digiti minimi (ADM), opponens digiti minimi, flexor digiti minimi, lumbricals to the ring, and little fingers. In addition to low level palsy, the following units are affected in high level ulnar palsy: Flexor digitorum profundus (FDP) to the little and ring finger, flexor carpi ulnaris. Some improvement in hand function, fine finger movements and hand appearance can be achieved by performing tendon transfers to ulnar palsy disease, which is not suitable for repair. The claw hand deformity is corrected by blocking the MCP hyperextension, which allows EDC extensor forces to be transmitted distally to the PIP and DIP via the extensor hood. The flexor digitorum superficialis (FDS) slips of the affected finger can be transected 2 cm proximal to their insertion and sutured to them proximally, creating a lasso around the A1 pulley [4]. We mostly use this procedure which is named Zancolli Lasso. Alternatively, the FDS of the long finger can be transected 2 cm proximal to its insertion and retracted proximally from the tendon sheath, and then redirected distally towards the intermetacarpal ligament and inserted into the radial lateral bands of the little and ring fingers (Stiles-Bunnell) [5]. Claw of all four digits (as seen in combined ulnar and low median nerve palsy) can be treated using flexor carpiradialis (FCR), or the extensor carpiradialis brevis(ECRB) tendon can be split into two to four tails depending on the number of fingers handled. The tails are then extended using free tendon grafts and attached to the radial lateral bands of the small, ring and long fingers and to the ulnar lateral band of the index finger (Brand) [6].

The power pinching (normally achieved by the ulnar innervated adductor pollicis, the 1<sup>st</sup> dorsal interosseous and the deep head of the FPB) can be addressed using the ECRB or FDS for an adductorplasty [7]. ECRB adductorplasty is performed by removing the ECRB from its insertion at the base of the second metacarpal and retrieving the proximal extensor retinaculum. A free tendon graft is then used as an extension at the end of the ECRB tendon and is directed distally between the third and fourth metacarpals and attached to the adductor pollicis insertion on the first metacarpal [8]. We have always used this technique for the thumb adductorplasty. Alternatively, FDS adductorplasty can be done using the long finger FDS. The index finger is abducted by transferring extensor indicis proprius (EIP) to the first interosseous unit that does not work due to ulnar paralysis. In this way, it contributes to the key pinch. Deep flexor tendons of ring and little fingers, which contribute to strong grip, are strengthened by tenodesis at wrist level.<sup>3</sup> Wartenberg's sign is generally present in ulnar palsy and has been associated with paralysis of the 3<sup>rd</sup> palmar interosseous. As a result of the unrivaled operation of the extensor digiti minimi (EDM), inaccurate abduction of the little finger occurs. If the Wartenberg finding is not accompanied by claw hand deformity, the EDM tendon can be prevented by doing tenodesis to the radial side of the little finger or the edm tendon EDC. If the Wartenberg sign accompanies the claw hand deformity, the ulnar side of the EDM tendon is separated from the retinaculum level. Then, it is passed between the 4th and 5th metacarpals and transferred from the palmar to A2 pulley. In this way, both MP flexion and little finger adduction are provided [9].

**Materials and Methods:** All patients, who underwent tendon transfers for unrepairable ulnar nerve palsy by highly experienced (level 5) same hand surgeon (KE) between 2012 and 2018, were retrospectively analyzed [10]. The patients have been given detailed information about the study, the written informed consent was obtained from all participants. This study was approved by the local ethics committee (Date: 07.05.2019, approval no: 2019/9-13). Our criteria for inclusion in the study: ulnar palsy high or low, no other nerve injuries and no fractures. The average age of 14 patients, 3 female and 11 male, was 35 (min: 22 max: 59) years. While the average time from injury to tendon transfer was 6.7 (min: 2 max: 20) years, our postop follow-up period was 5 (min:2 max: 8) years on average. Ten patients with penetrating injuries, 3 patients had trauma and 1 patient had gunshot injury etiology. Five of

the patients were operated from the left hand and 9 from the right side. While 6 of the patients had low level palsy, 8 had high level ulnar nerve palsy. The preoperative hand deformities of the patients and the tendon transfer methods performed were retrospectively obtained from the patients' files and evaluated. The last examinations and tests of the patients were performed in our clinic after their consent was obtained. Claw hand presence, Froment sign, Wartenberg sign, key pinch test, strong grip strength measurement, hand Quick Dash (QD) test, satisfaction questioning, paper squeezing and complications were evaluated in the examinations of the patients. Patients's strong grip test compared to healthy hand were evaluated. Grip strength was measured using a dynamometer. The key pinch test was also measured by comparing it to the healthy side with a special dynamometer device. Claw hand presence was clinically observed. Complications assessed during follow-up were swan neck deformity, contracture of the PIP joint, undercorrection resulting in recurrent clawing and joint stiffness.

**Results:** For claw hand deformity, 11 patients underwent Zancolli lasso procedure using FDS-3 split. In

2 patients, the FDS-4 and FDS-5 splits for the claw hand were underwent tenodesis on A1 pulley (Figure 1). In one patient, palmar 3<sup>rd</sup> interosseous tenodesis was performed as EDC-2 split in order to correct the 5<sup>th</sup> finger adductorplasty and claw hand deformity. The EDM tendon was directed to the palmar side and transferred to the A2 pulley for the Wartenberg sign in all patients except one patient (Figure 2). For that one patient's claw hand deformity and wartenberg sign, the EDC-2 tendon was split transferred to the 3<sup>th</sup> palmar interosseous. In 8 patients with high-level ulnar palsy, tenodesis was underwent with the other 2<sup>nd</sup> and 3<sup>rd</sup> FDP to strengthen the 4<sup>th</sup> and 5<sup>th</sup> FDP at the wrist level (Figure 3). Tenodesis was performed in 12 patients using ECRB tendons for thumb adductorplasty. After the ECRB tendon was lengthened with PL autograft, it was passed between the 3<sup>rd</sup> and 4<sup>th</sup> metacarpals to the volar of the hand and which was transferred to thumb adductor tubercle (Figure 4,5). The EIP tendon was transferred to the 1<sup>st</sup> interosseous in 12 patients for 2<sup>nd</sup> finger abduction (Figure 6). Transfer methods and some of the demographic data are given in the table (Table 1).

**Table 1: Surgical techniques according to deformities**

PN	A/G	Palsy level	Key pinch		Wartenberg sign	Claw hand	Strengthening the grip
			Thumb adductorplasty	Index finger abduction			
1	22/M	L	ECRB*	-	EDM>little finger A2 pulley	FDS-3 splits>4 <sup>th</sup> 5 <sup>th</sup> A1 pulley	-
2	31/M	H	ECRB*	EİP>1 <sup>st</sup> interosseous	EDM>little finger A2 pulley	FDS-3 splits>4 <sup>th</sup> 5 <sup>th</sup> A1 pulley	2 <sup>nd</sup> -5 <sup>th</sup> FDP tenodesis zone 6
3	34/F	H	ECRB*	EİP>1 <sup>st</sup> interosseous	EDM>little finger A2 pulley	FDS-3 splits>4 <sup>th</sup> 5 <sup>th</sup> A1 pulley	2 <sup>nd</sup> -5 <sup>th</sup> FDP tenodesis zone 6
4	37/F	L	-	-	EDM>little finger A2 pulley	FDS-3 splits>4 <sup>th</sup> 5 <sup>th</sup> A1 pulley	-
5	59/M	H	ECRB*	EİP>1 <sup>st</sup> interosseous	EDM>little finger A2 pulley	FDS-3 splits>4 <sup>th</sup> 5 <sup>th</sup> A1 pulley	2 <sup>nd</sup> -5 <sup>th</sup> FDP tenodesis zone 6
6	20/M	H	ECRB*	EİP>1 <sup>st</sup> interosseous	EDM>little finger A2 pulley	FDS-3 splits>4 <sup>th</sup> 5 <sup>th</sup> A1 pulley	2 <sup>nd</sup> -5 <sup>th</sup> FDP tenodesis zone 6
7	27/M	H	ECRB*	EİP>1 <sup>st</sup> interosseous	EDM>little finger A2 pulley	FDS-3 splits>4 <sup>th</sup> 5 <sup>th</sup> A1 pulley	2 <sup>nd</sup> -5 <sup>th</sup> FDP tenodesis zone 6

Serdar Karaman et al./The Clinical Results of Tendon Transfers in Patients with Ulnar Palsy

8	25/ M	H	ECRB*	EİP>1 <sup>st</sup> interosseous	EDM>little finger A2 pulley	FDS-3 splits>4 <sup>th</sup> 5 <sup>th</sup> A1 pulley	2 <sup>nd</sup> -5 <sup>th</sup> tenodesis zone 6	FDP
9	50/ M	L	ECRB*	EİP>1 <sup>st</sup> interosseous	EDM>little finger A2 pulley	FDS-3 splits>4 <sup>th</sup> 5 <sup>th</sup> A1 pulley	-	
10	45/ M	L	-	EİP>1 <sup>st</sup> interosseous	EDC-2 split>3 <sup>th</sup> interosseous	EDC-2 split>3 <sup>th</sup> interosseous	-	
11	49/M	H	ECRB*	EİP>1 <sup>st</sup> interosseous	EDM>little finger A2 pulley	FDS-3 splits>4 <sup>th</sup> 5 <sup>th</sup> A1 pulley	2 <sup>nd</sup> -5 <sup>th</sup> tenodesis zone 6	FDP
12	38/ F	H	ECRB*	EİP>1 <sup>st</sup> interosseous	EDM>little finger A2 pulley	FDS-3 splits>4 <sup>th</sup> 5 <sup>th</sup> A1 pulley	2 <sup>nd</sup> -5 <sup>th</sup> tenodesis zone 6	FDP
13	42/ M	L	ECRB*	EİP>1 <sup>st</sup> interosseous	EDM>little finger A2 pulley	FDS-4, 5 >4 <sup>th</sup> 5 <sup>th</sup> A1 pulley	-	
14	24/ M	L	ECRB*	EİP>1 <sup>st</sup> interosseous	EDM>little finger A2 pulley	FDS-4, 5 >4 <sup>th</sup> 5 <sup>th</sup> A1 pulley	-	

Patient number (PN), Age(A), gender(G), male(M), female(F), high(H), low(L), extensor carpi radialis brevis(ECRB), PL tendon was used for autograft(\*), extensor indicis proprius(EİP), brachioradialis(BR), extensor digiti minimi(EDM), extensor digitorum communis(EDC).

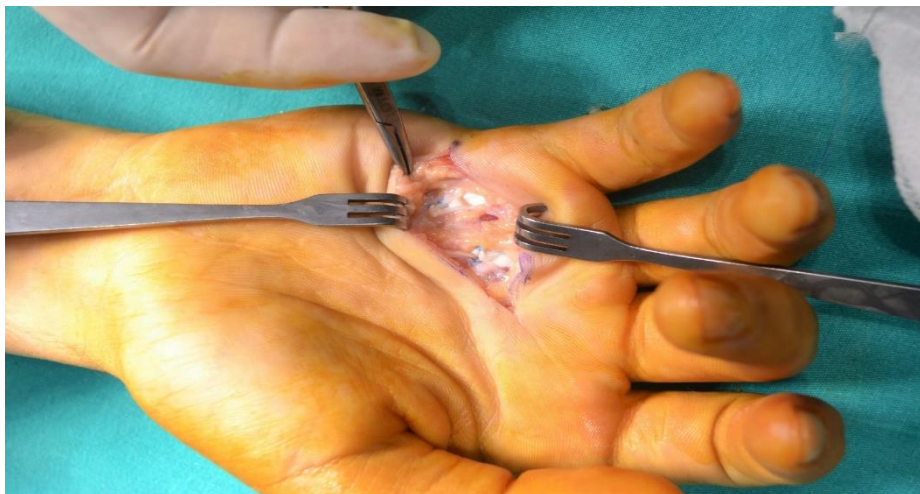

Figure 1: The FDS-4 and FDS-5 tendon used for the claw hand were underwent tenodesis on A1 pulley. (PN:14)

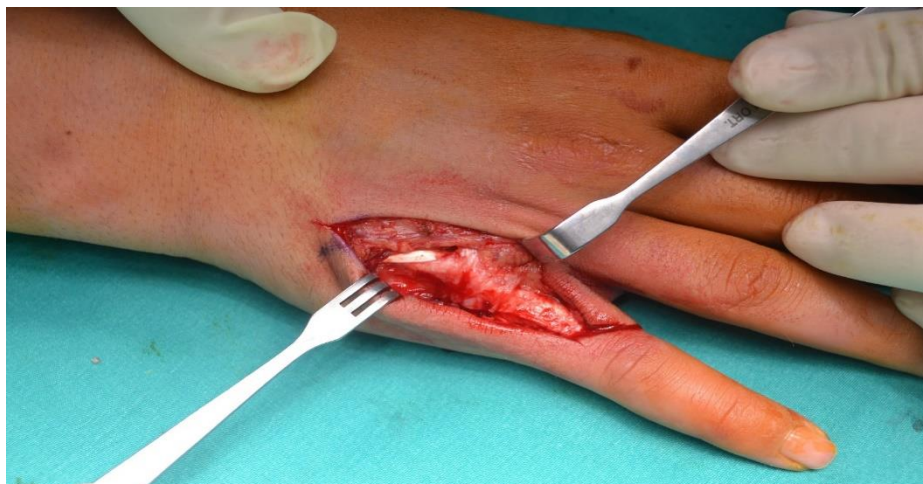

Figure 2: The EDM tendon transfer to A2 Pulley for small finger abduction and MCP flexion. (PN: 6)



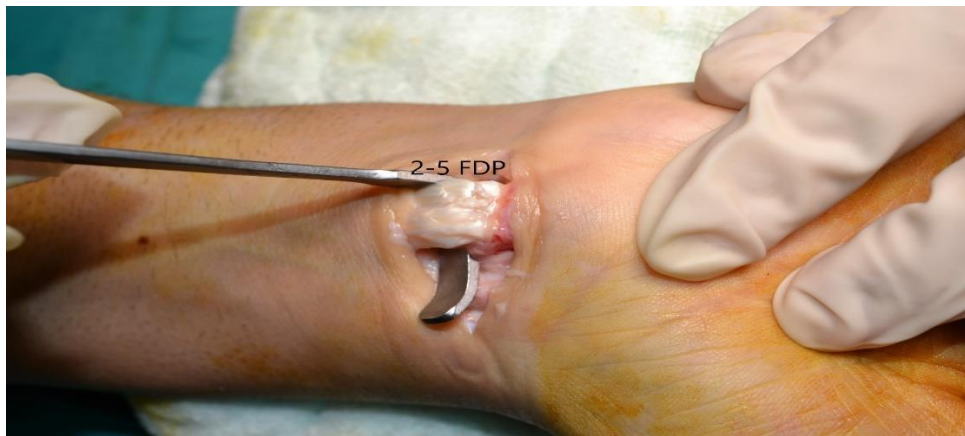


Figure 3 : The 2nd -5th FDP tendons tenodesis at wrist level (PN: 2)

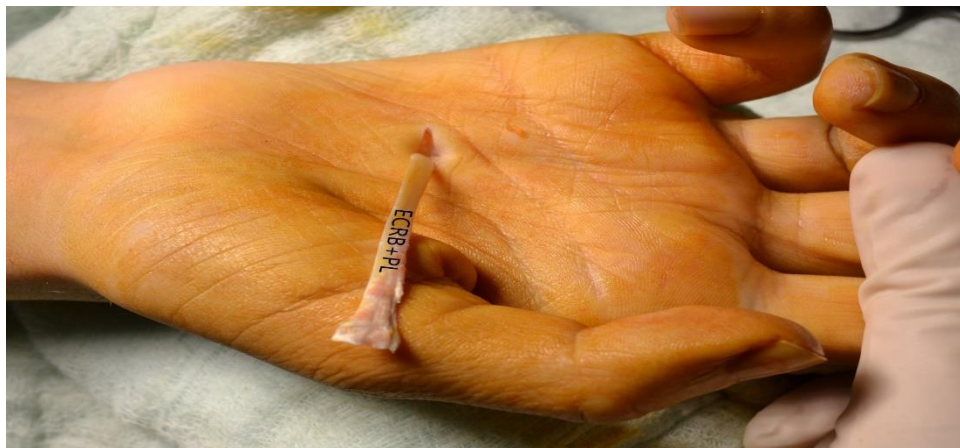

Figure 4 : for thumb adductorplasty, the ECRB tendon is passed through the intermetacarpal space between the third and fourth metacarpals (PN: 8)

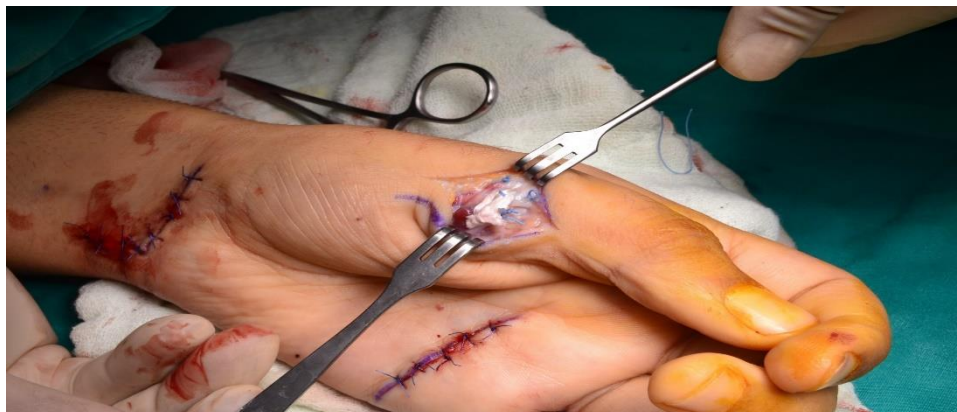

Figure 5 : The ECRB tenodesis at 1st metacarp adductor tubercle. (PN: 6)

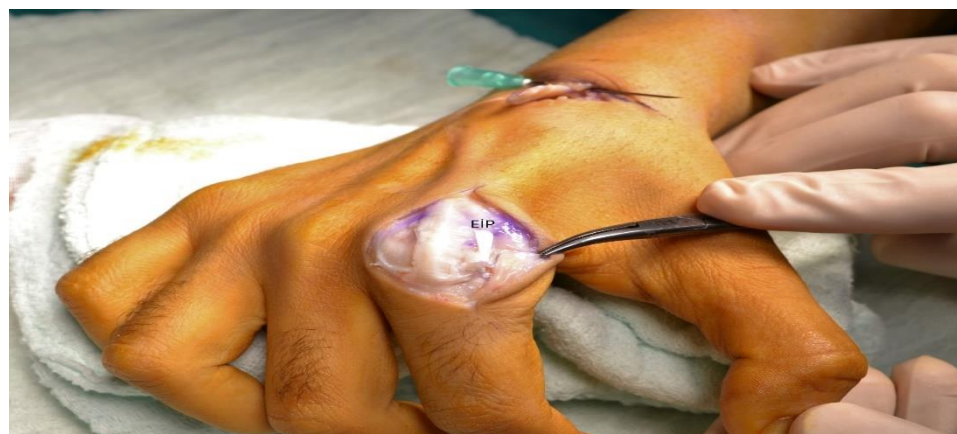

Figure 6 : The EIP tendon transferred to the 1st interosseous. (PN: 3)

No claw hand deformity was found in any of our patients, except the patient who was injured with a gunshot. The Zancolli lasso procedure was underwent to this patient who had the worst adherence to postoperative rehabilitation. One of these patients had flexion contracture in the 5<sup>th</sup> finger PIP joint. The Wartenberg sign and swan neck deformity were not found in any of the patients at their last examination (Figure 7,8).

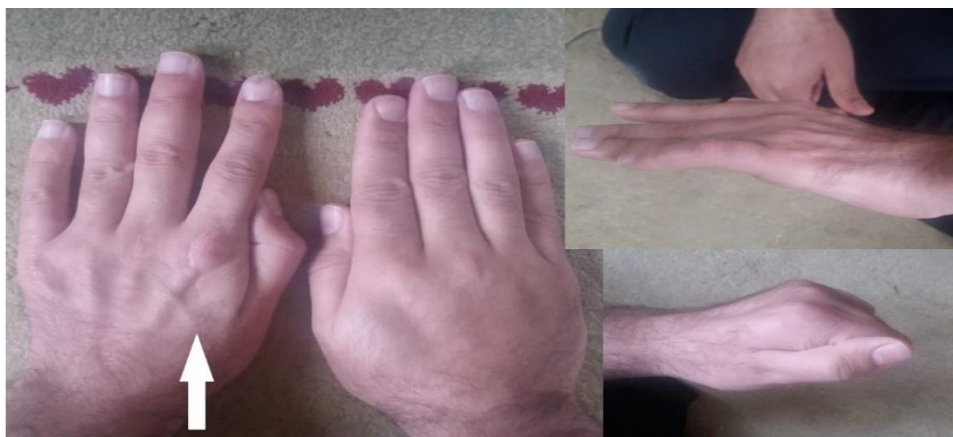

Figure 7: Postop figures of patient who has no claw hand, no Wartenberg sign and no Froment sign. (White arrow: affected side) (PN: 2)

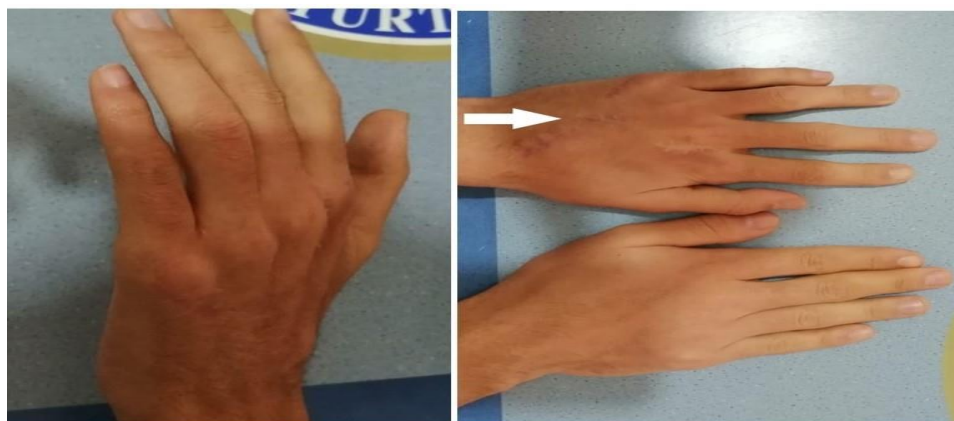


Figure 8: Postop figures of patients who has low ulnar palsy. (PN: 9) (White arrow: affected side)

The strong grip measurement was evaluated as %62.7 (max: 85 min: 22) on average compared to the opposite hand. Postop Quick-DASH mean scores of the patients were evaluated as 36.8 (max: 45 min: 9.5). Postop Key-Pinch test mean scores of the patients were evaluated as % 63.4 (max: 90 min: 33) on average compared to the opposite hand (Table 2). Two of the patients who underwent the first interosseous transfer using only the EIP tendon had hyperabduction in the second finger (Figure 9.). All of our patients had surgical scarring, it was remarkable because the hands had atrophy and they were not satisfied with this situation. Satisfied, moderately satisfied and dissatisfied were asked three parameters in the satisfaction evaluation of the patients. Seven (%50) of the patients were satisfied, 5 (%36) patients were moderately satisfied and two (%14) patients were not.



Figure 9: Postop figure of patients who has hiperabduction of index finger. (White arrow: affected side and hiperabduction of finger) (PN: 5)

**Table 2: Postop functional tests and scoring**

PN	Strength grip test (% opposite hand)	Pinch test (% opposite hand)	Quick Dash score
1	%75	%80	11,5
2	%22	%45	45
3	%45	%65	40
4	%80	%90	11,5
5	%50	%40	36,4
6	%66	%70	9,5
7	%65	%65	9,5
8	%40	%65	52,3
9	%65	%70	45
10	%65	%33	45
11	%70	%50	36,4
12	%70	%65	11,5
13	%80	%70	9,5
14	%85	%80	9,5

**Discussion:** Many dynamic and static methods have been described for the correction of claw hand deformity. Brand's technique using ECRL, Bunnel's technique and the Modified Zancolli Lasso technique using FDS tendon are among the most used and known methods [4, 5, 6]. Brand's technique, in which the ECRL tendon is used, is a very good motor for MCP flexion. However, it requires a free tendon graft like PL for its application and it is a difficult tendon to isolate [4]. In these techniques where wrist extensors are used and extended with free grafts, the carpal tunnel is passed. Therefore, it may lead to the risk of median nerve damage and increased pressure in the tunnel [11]. The FDS tendon used in the Bunnel and Zancolli technique is sufficient for MCP flexion and may be thicker than the PL graft even if it is divided into 4 parts. In addition, when FDS is used as a motor, the collection of the graft is prevented and tendon excursion is better. The zancolli lasso technique was used in most of the patients in the study and it was successful. The splits of FDS-4 and FDS-5 used in 2 patients were successful in claw hand correction. This new lasso technique, in which the 4th and 5th tendons were used separately, was not encountered in the literature and it was found to be successful in this technique [7, 12, 13].

Small finger abduction is caused by the paralysis of the third palmar interosseous, which subsequently causes the EDM to be retracted unrequited. The authors' preferred method to correct little finger abduction involves transferring the EDM to the radial direction of the small finger [14, 15]. In the Blacker's study; the tendon was passed to the palmar side of the MCP joint, if the joint could be hyperextended (claw hand); if not, a simple transfer to the radial collateral ligament was performed. Since there was claw hand in all our cases, the EDM tendon was directed to the palmar side and transferred to the A2 pulley. We found that this technique was successful in thirteen patients.

Many methods have been described for thumb adductorplasty. These methods include using FDS, BR, EDC and ECRB tendons [8, 16, 17]. But it is most advantageous to use ECRB. Using as the second metacarpal pulley, the transfer is oriented according to the original pulling direction of the adductor pollicis [8]. The Smith's technique has been modified by Omer in two ways: the tendon graft is passed through the intermetacarpal space between the third and fourth metacarpals; and the graft is guided on the back of the thumb and sutured to the fascia over the abductor tubercle of the thumb metacarpal for better pinching [18]. We used



this method, which proved to provide more options for thumb adductoplasty. For thumb adductor plasty, ECRB was transferred using the Omer technique in all patients. The contribution of index finger abduction to pinch is important, and it is provided again by the transfer of the first interosseous EIP tendon [8]. It was observed that the average key pinch (percentage of the opposite hand) was % 63.4 in patients. In ulnar nerve palsy, grip weakness is

one of the most important diseases and can be reduced by %60 to %80 in high ulnar nerve palsy at 8 and %38 in low ulnar nerve palsy [19]. The average strong grip of the patients (relative to the opposite hand) was measured at % 62.7. Many methods of tendon transfer are recommended in non-repairable ulnar palsy. The method we prefer is as in the table (Table 3).

**Table 3: Preferred tendon transfer method in ulnar palsy**

Deformity	Claw hand	Key pinch		Small finger abduction	Strength grip (high level palsy)
		Thumb adduktorplasty	Index finger abduction		
<b>Surgical Technique</b>	FDS-3 splits> 4 <sup>th</sup> , 5 <sup>th</sup> A1 pulley tenodesis	ECRB> abductor tubercule of metacarpal	EIP>1 <sup>st</sup> dorsal interosseous	EDM>A2 pulley	2 <sup>nd</sup> -5 <sup>th</sup> FDP tenodesis at wrist level

The low number of patients and the fact that they were not compared with other transfer techniques were the limitations of our study. Peripheral nerve injuries; it is repaired in the early period due to the developing healthcare system and increasing hand surgeons. Therefore, the number of patients with ulnar nerve injuries that cannot be repaired has gradually decreased. In addition, infectious diseases causing neuropathy such as leprosy are now rare. Case series of ulnar palsy with the highest number of patients in the literature are caused by leprosy [20, 21].

In conclusion, different patients have different functional defects, ranging from aesthetic concerns after ulnar nerve palsy to significant weakness in pinching. When dealing with the sequelae of late ulnar nerve palsy, each patient's needs should be carefully evaluated, taking care to address the necessary issues. There are multiple treatment options available to restore function, and a single method cannot be applied to every case.

**References:**

1. Gottschalk HP, Bindra RR. Late reconstruction of ulnar nerve palsy. *Orthop Clin North Am.* 2012 Oct;43(4):495-507. doi: 10.1016/j.ocl.2012.08.001. Epub 2012 Sep 4. PMID: 23026465.
2. Markey AC, Glogau RG. Autologous fat grafting: comparison of techniques. *Dermatol Surg.* 2000 Dec;26(12):1135-9. PMID: 11134990.
3. Sammer DM, Chung KC. Tendon transfers: Part II. Transfers for ulnar nerve palsy and median nerve palsy. *Plast Reconstr Surg.* 2009 Sep;124(3):212e-221e. doi: 10.1097/PRS.0b013e3181b037c7. PMID: 19730287; PMCID: PMC2741332.
4. ZANCOLLI EA. Claw-hand caused by paralysis of the intrinsic muscles: a simple surgical procedure for its correction. *J Bone Joint Surg Am.* 1957 Oct;39-A(5):1076-80. PMID: 13475406.
5. Bunnell S. Surgery of the intrinsic muscles of the hand other than those producing opposition of the thumb. *J Bone Joint Surg Am* 1942; 24A: 1–31
6. BRAND PW. Paralytic claw hand; with special reference to paralysis in leprosy and treatment by the sublimis transfer of Stiles and Bunnell. *J Bone Joint Surg Br.* 1958 Nov;40-B(4):618-32. doi: 10.1302/0301-620X.40B4.618. PMID: 13610974.
7. Sachar K. Reconstruction for ulnar nerve palsy. In: Berger RA, Weiss AP, editors. *Hand surgery.* Philadelphia: Lippincott Williams & Wilkins; 2004. P: 979–90.
8. Smith RJ. Extensor carpi radialis brevis tendon transfer for thumb adduction--a study of power pinch. *J Hand Surg Am.* 1983 Jan;8(1):4-15. doi: 10.1016/s0363-5023(83)80044-6. PMID: 6827050.



9. Dellon AL. Extensor digiti minimi tendon transfer to correct abducted small finger in ulnar dysfunction. *J Hand Surg Am.* 1991 Sep;16(5):819-23. doi: 10.1016/s0363-5023(10)80142-x. PMID: 1658117..
10. Tang JB, Giddins G. Why and how to report surgeons' levels of expertise. *J Hand Surg Eur Vol.* 2016 May;41(4):365-6. doi: 10.1177/1753193416641590. PMID: 27076602..
11. Malaviya GN. Median nerve palsy following claw finger correction in leprosy: effect of *M. leprae* or a consequence of surgery. *Indian J Lepr.* 2002 Jul-Sep;74(3):217-20. PMID: 12708700..
12. Gottschalk HP, Bindra RR. Late reconstruction of ulnar nerve palsy. *Orthop Clin North Am.* 2012 Oct;43(4):495-507. doi: 10.1016/j.ocl.2012.08.001. Epub 2012 Sep 4. PMID: 23026465..
13. Sammer DM, Chung KC. Tendon transfers: Part II. Transfers for ulnar nerve palsy and median nerve palsy. *Plast Reconstr Surg.* 2009 Sep;124(3):212e-221e. doi: 10.1097/PRS.0b013e3181b037c7. PMID: 19730287; PMCID: PMC2741332..
14. Blacker GJ, Lister GD, Kleinert HE. The abducted little finger in low ulnar nerve palsy. *J Hand Surg Am.* 1976 Nov;1(3):190-6. doi: 10.1016/s0363-5023(76)80037-8. PMID: 1018086..
15. Gonzalez MH, Gray T, Ortinou E, Weinzeig N. The extensor tendons to the little finger: an anatomic study. *J Hand Surg Am.* 1995 Sep;20(5):844-7. doi: 10.1016/S0363-5023(05)80441-1. PMID: 8522754..
16. Boyes JH. *Bunnell's surgery of the hand.* 5th edition. Philadelphia: Lippincott; 1970.
17. LITTLER JW. Tendon transfers and arthrodeses in combined median and ulnar nerve paralysis. *J Bone Joint Surg Am.* 1949 Apr;31A(2):225-34. PMID: 18116560..
18. Omer GE. Ulnar nerve palsy. In: Green DP, Hotchkiss WC, Pederson WC, editors. *Green's operative hand surgery.* 4th edition. New York: Churchill Livingstone; 1999. p. 1526–41.
19. Kozin SH, Porter S, Clark P, Thoder JJ. The contribution of the intrinsic muscles to grip and pinch strength. *J Hand Surg Am.* 1999 Jan;24(1):64-72. doi: 10.1053/jhsu.1999.jhsu24a0064. PMID: 10048518..
20. Taylor NL, Raj AD, Dick HM, Solomon S. The correction of ulnar claw fingers: a follow-up study comparing the extensor-to-flexor with the palmaris longus 4-tailed tendon transfer in patients with leprosy. *J Hand Surg Am.* 2004 Jul;29(4):595-604. doi: 10.1016/j.jhsa.2004.03.006. PMID: 15249082..
21. Ozkan T, Ozer K, Yukse A, Gulgonen A. Surgical reconstruction of irreversible ulnar nerve paralysis in leprosy. *Lepr Rev.* 2003 Mar;74(1):53-62. PMID: 12669933..

### Highlights:

- Tenodesis of FDS-4 and FDS-5 to A1 pulley was successful for the claw hand in low level ulnar palsy.
- We believe that the EDM tendon both prevents little finger abduction (Wartenberg sign) and contributes to the little finger MCP flexion with A2 pulley tenodesis.
- It was found that tenodesis of the 2<sup>nd</sup>-5<sup>th</sup> FDP tendons at the wrist level significantly increased the grip strength of the patients in high-level ulnar palsy.