



## Case Report

# MALT lymphoma revealed by parotidomegaly in patients with Sjögren's syndrome

Rim Braham<sup>1\*</sup>, Esma Jameleddine<sup>1</sup>, Sameh Sayhi<sup>2</sup>, Rania Ben Mhamed<sup>1</sup>, Khemaies Akkari<sup>1</sup> and Sameh Mezri<sup>1</sup>

<sup>1</sup>University Tunis Manar,  
Faculty of Medicine Tunis,  
Department of Otolaryngology  
and maxillofacial Surgery,  
Military Hospita, Tunis, Tunisia

<sup>2</sup>University Tunis Manar,  
Faculty of Medicine Tunis,  
Department of Internal  
Medicine, Military Hospital,  
Tunis

### Abstract

**Introduction:** The occurrence of non-Hodgkin's malignant lymphoma in patients with Gougerot-Sjögren Syndrome is not uncommon, and some predictive factors may point the practitioner towards the risk of possible degeneration. We report two cases of patients followed for primary Sjögren's syndrome who developed parotid MALT lymphoma. **Results:** Two patients aged 29 and 64 years followed for Sjögren's syndrome. The first one was under azathioprine while the second was treated with corticosteroids. After a follow-up of 13 months and 9 years, respectively, patients consulted for aggravation of a pre-existing bilateral parotid swelling which became hard and sensitive and was accompanied with alteration of the general state of health. They were explored by a biological assessment and magnetic resonance imaging of the parotids. The parotid gland biopsy concluded that a MALT-type lymphoma turned into a large-cell B-lymphoma in one case and small-cell B-lymphoma in the other case. The treatment was based on chemotherapy with favorable evolution. **Conclusion:** The Sjögren's syndrome is recognized as a pre-lymphomatous state on which MALT lymphomas from the marginal area are frequently added. Degeneration must be suspected in front of predictive lymphomatous transformation elements. Early management is essential to improve prognosis of connectivitis and lymphoma.

**Keywords:** Sjögren's syndrome, MALT lymphoma, Marginal Zone Lymphoma

Copyright : © 2022 The Authors. Published by Publisher.  
This is an open access article under the CC BY-NC-ND  
license  
(<https://creativecommons.org/licenses/by-nc-nd/4.0/>).

**Supplementary information** The online version of this article (<https://doi.org/xx.xxx/xxx.xx>) contains supplementary material, which is available to authorized users.

**Corresponding Author:** Rim Braham, *MALT lymphoma revealed by parotidomegaly in patients with Sjögren's syndrome*

## **Introduction:**

Sjögren's syndrome (SS) is a connective tissue disease, characterized by the presence of a lymphocytic infiltrate, which mainly affects the exocrine glands. According to the American-European Consensus Criteria (AECC), 0.5% of adults have SS [1]. Its etiopathogenesis has not yet been clearly elucidated, but the major risk remains the development of non-Hodgkin's lymphoma (NHL). All series have noted a significantly higher rate of lymphoma in patients with SS than in the general population [1-3].

The lymphomatous locations are often extranodal with preferential involvement of the salivary glands. In patients with SS for more than 10 years, the frequency of NHL is in the order of 5-10%, and this rate increases with the time of evolution [1]. However, several clinical and biological signs have been identified as predictive of lymphomatous transformation.

Through this study, we report two cases of MALT lymphoma discovered in two patients followed for Sjögren's syndrome, aged 29 and 64 years upon the development of a bilateral parotidomegaly. Thus, we insist on the importance of evoking the diagnosis of lymphomatous degeneration from the first clinical and/or biological signs to ensure an early management and improve the prognosis of the disease.

## **Observation 1:**

A 29-year-old female patient with no notable pathological history was admitted for investigation of long-standing fever with polyarthritis.

The history goes back 3 years marked by inflammatory polyarthralgias with xerostomia and xerophthalmia; the patient was put on a symptomatic treatment without improvement.

On examination, she was febrile at 38.2°C with mucocutaneous pallor and bilateral homogeneous and painless parotid hypertrophy associated with livedo on all four limbs. Were also noted vascular purpura of the two lower limbs and arthritis of the ankles, wrists, metacarpophalanges (MCP) and proximal interphalanges (IPP). The biology showed a sedimentation rate (SV) of over 150 mm at the first hour and a C-reactive protein (CRP) of 100 mg/l.

The immunological work-up revealed positive anti-SSA and anti-SSB, anti-DNA and rheumatoid factor (RF) were negative.

The diagnosis of primary SS was based on xerostomia, xerophthalmia, positive antiSSA and antiSSB, hypocaptation of the salivary glands on scintigraphy, advanced lymphocytic infiltration on lip biopsy, and the absence of signs of another connective tissue disease.

Given the presence of purpura, the patient was put on prednisone 0.5 mg/Kg/day with an improvement of the symptomatology.

The evolution was marked by the recurrence of arthralgia after a few months and fever with exaggeration of the parotid hypertrophy which had become inflammatory and sensitive. The patient was then put on prednisone: 1 mg/Kg/day without improvement.

In view of this picture, a lymphomatous transformation was suspected. The parotid gland biopsy concluded to a small cell lymphoma type MALT. The extension study was negative. The patient underwent chemotherapy with a good outcome.

## **Observation 2:**

A 64-year-old female patient who had been treated for 9 years with azathioprine-based immunosuppressive therapy, consulted for a recent and rapidly progressive worsening of a pre-existing bilateral parotid hypertrophy.

On examination, the patient reported an altered general condition with anorexia, significant asthenia, and weight loss.

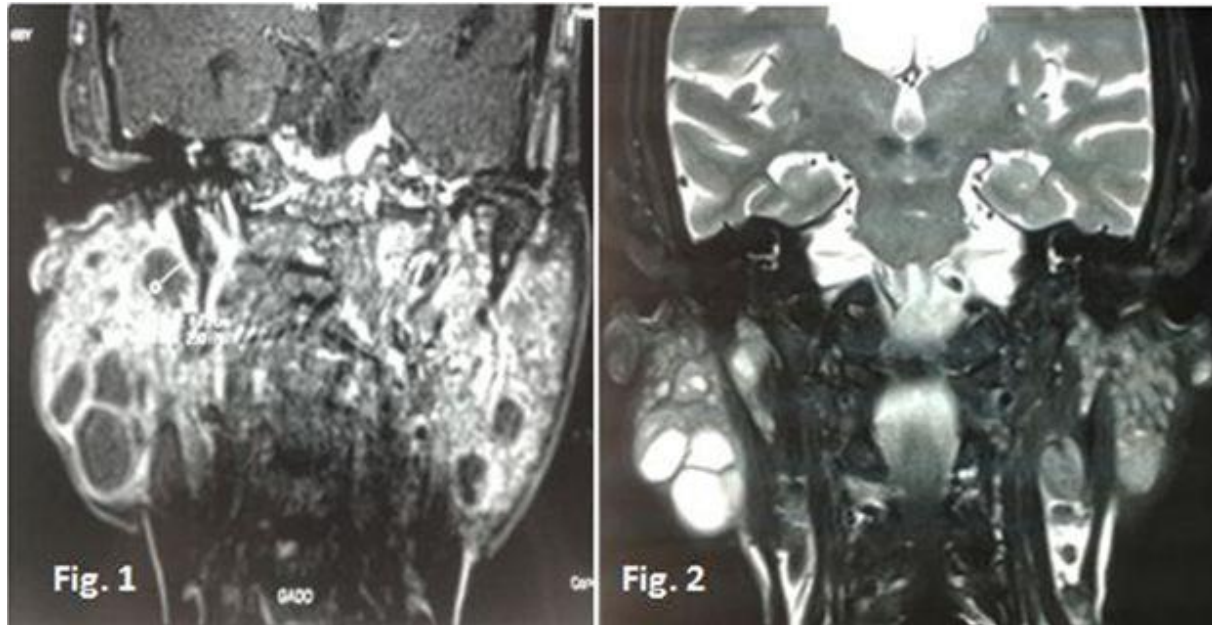
The physical examination revealed a bilateral parotidomegaly on the right side, 6 cm long, fixed, firm to hard, associated with a fixed mass in the right submental area of 5 cm long, of recent appearance.

The rest of the ENT examination was without abnormalities, particularly a healthy and free Stenon's orifice with no peripheral facial paralysis.

The biological work-up showed an elevated lactate dehydrogenase (LDH) level of 540U/l, a Beta 2 microglobulin of 19 mg/l. The haemogram showed a normocytic normochromic anemia at 9g/dl. The initially normal renal work-up deteriorated rapidly with a creatinemia of 30mg/L, a urea level of 3 g/L and a uric acid level of 156mg/L.

Protein electrophoresis showed a beta-gamma block with hypoalbuminemia without gamma-globulinemia peak.

A cervicofacial MRI had shown intraparotid nodules with a cystic component affecting both the superficial and deep lobes. They were T1 iso signal, T2 hypersignal with regular parietal enhancement. (Figures 1 and 2)



*Figures 1 and 2: Cervicofacial MRI coronal views in T1-weighted scans (Fig 1) and T2-weighted scans (Fig 2) showing parotid Tumor*

Because of the strong suspicion of lymphomatous transformation, the patient underwent a cervicotomy with excision of a right group IIa adenopathy, but the extemporaneous examination was non-contributory (non-metastatic, non-tuberculous). A right exofacial parotidectomy was therefore performed at the same time. The final pathological examination concluded to a MALT type lymphoma which had transformed into a large cell B lymphoma.

The extension work-up was negative (oesogastroduodenal fibroscopy, colonoscopy with staged biopsies, thoraco-abdomino-pelvic CT scan). In addition, the patient had a positive HIV serology discovered postoperatively for which she was treated with triple antiretroviral therapy. The patient was then referred to haematologists for further treatment with appropriate chemotherapy.

## **Discussion:**

The occurrence of non-Hodgkin's lymphoma (NHL) in patients with primary SS syndrome is well known since the work of Talal [4] and represents one of the most demonstrative examples of the relationship between autoimmune pathology and lymphoproliferative syndrome.

Several authors have studied the incidence of lymphomatous disease in these patients as well as the risk factors or precursors of a possible degeneration.

In a cohort study, Theander [3] followed 7 patients for an average of 8 years [1 month-19 years], they reported a 16-times higher incidence of lymphoma in the presence of SS than in the general population. This risk was 44-times higher in the series by Kassan [2], which included 142 patients followed for an average of 8 years.

Lymphoma can occur at any stage of the disease course, but the longer the history of the disease, the higher the incidence. After more than 10 years of disease progression, the incidence is in the order of 5 to 10% [1]. In one of our patients, however, the delay between the diagnosis of the two conditions was 13 months.

Certain clinical and biological signs have been identified as predictive of cancer and their demonstration can guide the treating physician to evoke early the diagnosis of lymphomatous degeneration.

As it was the case for our two patients, parotidomegaly is one of the most reported signs, whether or not associated with a tumoral syndrome like splenomegaly and/or polyadenopathy. General signs such as unexplained prolonged fever, arthralgia or anorexia with weight loss are also warning signs but are not common [5].

Gottenberg [6], on the other hand, has emphasized on the frequency of silent forms of the disease even in advanced stage of the lymphoma on imaging, which partly explains the delayed diagnosis in most cases. Thus, several authors draw attention to the importance of considering biological markers instead. In fact, the appearance of a monoclonal immunoglobulin or, on the contrary, the collapse of immunoglobulin levels and the disappearance of autoantibodies, the appearance of free light chains in the urine or the significant rise in beta-2-microglobulin may be elements that predict the appearance of a lymphoma [6,7]. In our case, only one patient had a peak microglobulinemia of 19 mg/L associated with anemia, which was found in both patients.

The appearance of cryoglobulinemia also seems to be an important predictive factor. In patients with SS, mixed cryoglobulinemia (type II) was present in 86% of cases with lymphomatous transformation, whereas it was found in only 12% of patients without transformation [8]. Signs such as anemia, lymphopenia, and a decrease in C3 and C4 fractions are also indicative of the onset of lymphoid proliferation [7,8]. In Theander's series [3], signs statistically associated with lymphogenesis were the presence of vascular purpura, a decrease in CD4 and CD8 with a CD4/CD8 ratio  $\leq 0.8$  and a complement fraction C3 level below 0.83 g/l ( $p < 0.05$ ).

The localizations of non-Hodgkin's lymphoma are essentially those of the disease (salivary glands, lacrimal glands, etc.) and then the mucous membranes. In the light of the new histological classifications of lymphomas, it appears that most lymphomas complicating SS are represented by marginal zone lymphomas: mucosal lymphoma of the MALT type or low-grade monocytoid lymph node or directly seen at the stage of transformation into large-cell lymphoma like our patient [9]. Although the lymphocytic infiltration of the salivary glands is predominantly T CD4, these are B lymphomas.

To explain the pathophysiology of the occurrence of lymphomas during this connective tissue disease, several hypotheses have been put forward; three types of events seem likely to trigger the carcinogenesis of a minority B clone that is probably present quite early in the disease:

- A viral event which has never been proven
- An oncological event via an acquired translocation t (14;18) responsible for increased cell survival by blocking apoptosis and/or a mutation of the tumour suppressor gene p53 which was present in patients with lymphoma [10].
- Or finally an immunological event via autoimmune activity of B lymphocytes which could explain the frequency of cryoglobulinemia type 2 and "auto-reactive" idiotypes in the blood of these patients; these auto-reactive B lymphocytes permanently stimulated by a self-antigen would be more likely to be transformed by an oncological event which differs from one patient to another [8].

In a more recent study, Saint-Marcoux draws attention to the role of T lymphocytes, which are responsible for activating B lymphocytes, leading to the appearance of a monoclonal population, through increased production of BlyS (B-lymphocyte stimulating factor) [11].

Once the diagnosis is confirmed by histological study, patients are usually treated with chemotherapy adapted to the grade of malignancy or with radiotherapy alone in the case of a single location. However, in low-grade lymphomas that are completely asymptomatic and have no systemic manifestations, no treatment may be warranted. The 5-year survival rate for low-grade malignant NHL associated with SS is over 50% [5]. Nonetheless, in a cohort of 723 patients with SS, 39 deaths were noted, 20% of which were attributable to lymphoma [12].

## Conclusion:

The association of a lymphoproliferative syndrome with Sjögren's syndrome represents a pattern of lymphomagenesis. The search for risk factors announcing this malignant transformation, will allow a better follow-up as well as an early and adequate management.

## References:

1. Vitali C, Bombardieri S, Jonsson R, Moutsopoulos HM, Alexander EL, Carsons SE, et al. Classification criteria for Sjogren's syndrome: a revised version of the European criteria proposed by the American-European Consensus Group. *Ann Rheum Dis* 2002 Jun;61(6):554–558
2. Kassan SS, Thomas TL, Moutsopoulos HM, Hoover R, Kimberly RP, Budmann DR et al. Increased risk of lymphoma in sicca syndrome. *Ann Intern Med*. 1978 Dec;89(6): 888-892.

3. Theander E, Henriksson G, Ljungberg O, Mandl T, Manthorpe R, Jacobsson L. Lymphoma and other malignancies in primary Sjogren's syndrome : a cohort study on cancer incidence and lymphoma predictors. *Ann Rheum Dis.* 2006 Jun;65(6):796-803.
4. Talal N, Sokoloff L, Barth WF. Extrasalivary lymphoid abnormalities in Sjogren's syndrome (reticulum cell sarcoma, « pseudolymphoma », macroglobulinemia). *Am J Med.* 1967 Jul;43(1):50-65.
5. Berrady R, Lamchacht L, Boukhrissa A, Khammar Z, Lahlou M, Rahbi S, et al. Lymphome parotidien révélé à l'occasion du diagnostic d'un syndrome de Gougerot-Sjogren. *Etude d'une observation. AMETHER.* 2009 Oct;1(1):32-34.
6. Gottenberg JE, Aucouturier F, Goetz J, Sordet C, Jahn I, Busson M et al. Serum immunoglobulin free light chain assessment in rheumatoid arthritis and primary Sjögren's syndrome. *Ann Rheum Dis.* 2007 Jan;66(1):23-7.
7. Grosbois B, Jego P, Leblay R. Syndrome de Gougerot-Sjögren et syndromes lympho prolifératifs malins. *Rev Med Interne.* 1998 May;19(5):319-324.
8. Moutsopoulos HM, Tzioufas AG, Boumba DS, Skopouli FN. Mixed monoclonal cryoglobulinemia and monoclonal rheumatoid factor cross reactive idiotypes as predictive factors for the development of lymphoma in primary Sjogren's syndrome. *Arthritis Rheum.* 1996 May;39(5):767-772.
9. Royer B, Cazals D, Silibia J, Agbalika F, Cayuela JM, Soussi T et al. Lymphoma in patients with Sjögren's syndrome are marginal zone B-cell neoplasms, arise in diverse extranodal and nodal sites, and are not associated with viruses. *Blood.* 1997 Jul;90(2):766-775.
10. Tapinos NI, Polihronis M, Moutsopoulos HM. Lymphoma development in Sjögren's syndrome. Novel p53 mutations. *Arthritis Rheum.* 1999 Jul;42(7):1466-1472.
11. Saint-Marcoux B, De Bandt M. Syndrome de Gougerot-Sjögren : critères de classification, lymphomes, traitements. *Rev de Rhum.* 2007 sep;74(8):737-744.
12. Ioannidis JP, Vassiliou VA, Moutsopoulos HM. Long-term risk of mortality and lymphoproliferative disease and predictive classification of primary Sjogren's syndrome. *Arthritis Rheum.* 2002 mar;46(3):741-747.