



Article Type
Case Report

Incidentally Morcellated High grade Leiomyosarcoma Treated by Cytoreductive Surgery and simultaneous Hyperthermic Intraperitoneal Chemotherapy

Răzvan Petru Derihaci¹ | Hüseyin Cengiz^{2,3} | Shadi Younes^{2,4} | Adriana Florentina Burcea⁵ | Anke Mothes⁶ | Julia Radosa⁷ | Bernd Reith⁸ | Nadja Dornhöfer⁹ | Alexandru Nechifor¹⁰ | Marc Radosa^{2,4*}

¹Department of Gynecology and Obstetrics, University Carl Gustav Carus, 01307 TU Dresden, Germany

²Department of Gynecology and Obstetrics, Agaplesion Diakonie Kliniken, Kassel, Germany

³Department of Gynecology and Obstetrics, Istanbul Aydin University, Istanbul, Turkey

⁴Department of Gynecology and Obstetrics, Klinikum Bremen-Nord, Bremen, Germany

⁵Department of Urology, University Carl Gustav Carus, 01307 TU Dresden, Germany ,

⁶Department of Gynecology, Eisenach Hospital, Eisenach, Germany

⁷Department of Obstetrics and Gynecology, Saarland University Hospital, Homburg, Germany

⁸Department of General Surgery, Agaplesion Diakonie Kliniken, Kassel, Germany

⁹Department of Gynecology, Leipzig University Hospital, Leipzig, Germany

¹⁰Faculty of Medicine and Pharmacy of the "Dunărea de Jos" University of Galați, Romania

Abstract

The incidental morcellation of uterine sarcomas during laparoscopic management of uterine tumors preoperatively misdiagnosed as benign fibroids constitutes a clinical challenge for the further oncological treatment and results in an iatrogenic tumor upstaging. Tumor cell dissemination in the abdominal cavity with the risk of a compromised oncologic outcome, constitutes a major clinical challenge in affected patients. In this report we present the case of a 49 year old patient, for whom a uterine morcellation was conducted as part of an endoscopic supracervical hysterectomy for the preoperative diagnosis of a symptomatic fibroid of the uterus. Postoperatively, final histopathologic exam revealed the presence of a high grade leiomyosarcoma in the uterine specimen. Further oncologic surgical treatment consisted of a median exploratory laparotomy with cytoreductive surgery (CRS) and an hyperthermic intraperitoneal chemotherapy (HIPEC). The postoperative course of the patient proved uneventful. HIPEC may complement CRS in patients with incidental uterine sarcoma morcellation. In our case, HIPEC was well tolerated and no tumor relapse was observed after three, six and twelve months postoperatively. Further studies are needed in order to evaluate the potential benefit of HIPEC in the oncologic treatment of patients with incidental morcellation of uterine sarcoma.

Keywords: High grade uterine leiomyosarcoma, morcellation, heated intraperitoneal chemotherapy, cytoreductive surgery, gynecology

Copyright : © 2022 The Authors. Published by Publisher. This is an open access article under the CC BY-NC-ND license (<https://creativecommons.org/licenses/by-nc-nd/4.0/>).

1 | INTRODUCTION

Uterine leiomyomas are the most common pelvic tumor in women (1) and they represent benign proliferations of the uterus that appear during the childbearing years. They are not associated with the risk of evolving into malignancy. The number, size and localization of the leiomyomas may vary from one patient to another.

Because they are asymptomatic in the majority of cases, the clinician may identify the fibroids accidentally during a routine pelvic examination. Depending of the symptoms and the clinical parameters of the patient, the treatment can and must be personalized and it can range from:

- watchful waiting for the women that do not experience signs or symptoms or, they have a mildly intensity
- medications that target the heavy menstruation and the pelvic pressure; might decrease the volume of the fibroids
- minimally invasive procedures like uterine artery embolization, radiofrequency ablation, laparoscopic or robotic myomectomy or endometrial ablation
- traditional surgical approach that consists from abdominal myomectomy and hysterectomy.

Laparoscopic supracervical hysterectomy is a minimally invasive approach used in the surgical management of the leiomyomas, that has decreased morbidity, shortened the hospital stay and provided quicker return to normal activities compared with an open abdominal surgical approach.

The ability to offer less invasive surgery often requires the removal of large tissue specimens through a small incision. A common tissue extraction technique in these minimal invasive interventions is by morcellation. Morcellation represents a technique that disintegrates the fibroids into small pieces, permitting the surgeon to extract them and avoiding to expand an incision.

The main concern regarding uterine morcellation is the dissemination of resected tissue in women surgically managed for presumed benign leiomyomas who are found postoperatively to have uterine sarcoma or other gynecological malignancies. Ac-

ording to Mayo Clinic, the risk of interfering with an undiagnosed malignancy is significantly lower in the young premenopausal women than in the older female patients.

The clinicians are faced with the important task of ruling out the possibility of uterine leiomyosarcoma (ULMS) or smooth muscle tumor of uncertain malignant potential (STUMP) preoperatively (2). Morcellation of uterine sarcoma appears to be associated with a worsened prognosis (3), though more data are needed to support this assertion. Because of its rarity, the understanding of leiomyosarcomas is still limited, and effective therapeutic regimens in the postoperative setting remain elusive (4).

In the past, cytoreductive surgery (CRS) and hyperthermic intraperitoneal chemotherapy (HIPEC) (Figure 1) have been successfully used in patients with gynecological pathology (5); however, there is limited literature pertaining to CRS/ HIPEC treatment with inadvertently morcellated ULMS.

The first step of this approach is to surgically remove the visible malignant growth – cytoreductive surgery (CRS) and then to release a powerful amount of chemotherapy directly into the abdomen by using the hyperthermic intraperitoneal chemotherapy method (HIPEC). After being heated to 42°C, the chemotherapy regimen is distributed directly into the peritoneal cavity, in the attempt to prevent the peritoneal dissemination of the malignant cells into the abdomen. The cytotoxicity of chemotherapy regimen that is equally distributed into the patient's abdomen is augmented by the hyperthermia and the intraperitoneal insertion permits the local carriage of higher doses than the ones that are administered systemically, in this manner the toxicity is minimized.

Supplementary information The online version of this article (<https://doi.org/xx.xxx/xxx.xx>) contains supplementary material, which is available to authorized users.

Corresponding Author: *Marc Radosa*
Department of Gynecology and Obstetrics, Agaplesion Diakonie Kliniken, Kassel, Germany
Department of Urology, University Carl Gustav Carus, 01307 TU Dresden, Germany

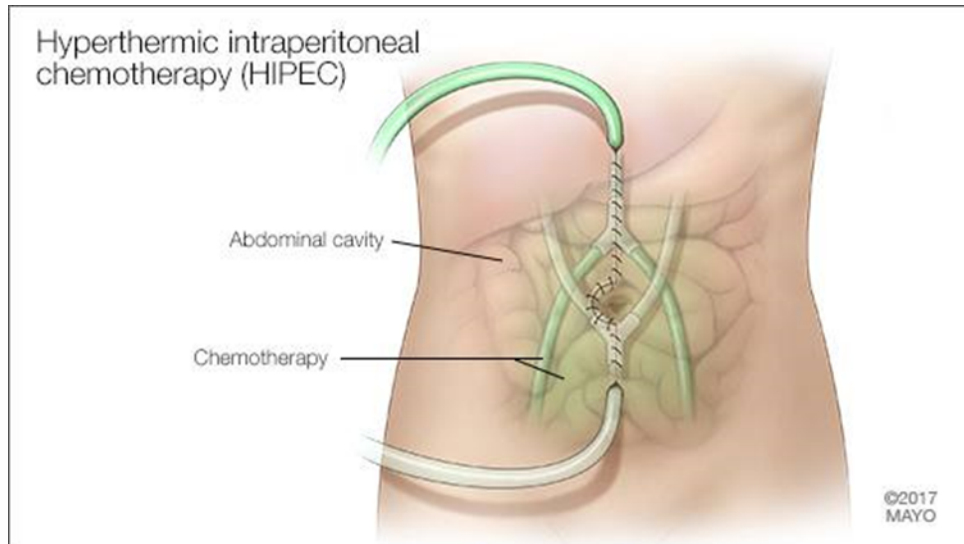


FIGURE 1: Illustration of the Hyperthermic intraperitoneal chemotherapy (HIPEC) according to MayoClinic

Furthermore, it is also unclear and remains elusive the optimal management of patients with inadvertently morcellated LMS/STUMP. Therefore, we present a case of high grade leiomyosarcoma after laparoscopic supracervical hysterectomy successfully treated with CRS/HIPEC.

2 | CASE PRESENTATION:

We illustrate the case of a 49-year-old multiparous woman with a history of an asymptomatic myoma measuring 4 x 3 cm, presented with complaints of worsening pelvic pain and menorrhagia in the last year after the initial diagnosis. Upon presentation in our department her myoma had increased in size to 5 x 6 cm. The computer tomography images are listed in the Figure 2.

She underwent laparoscopic supracervical hysterectomy Figure 3 with bilateral salpingectomy. Intraoperatively the uterus corpus was morcellated by using a Power Morcellator (Rotocut G1, Storz). The estimated blood loss intraoperatively was 150 mL and no postoperative complications occurred. She was discharged home on the next day of the surgery. Pathologic examination of the morcellated 257g specimen revealed the presence of a low differentiated, high-grade leiomyosarcoma, positive for estrogen receptor and progesterone receptor.

For the further management; evaluation included computed tomographic imaging of the thorax and the abdomen with no findings suspicious for additional sites of malignancy. Patient underwent an explorative laparotomy with cervical extirpation, bilateral adnexectomy, removal of eventual residual tissue and omentectomy with a concomitant hyperthermic intraperitoneal chemotherapy (HIPEC) as an individual healing attempt.

After ten days from the initial surgery, the patient underwent cytoreductive surgery (CRS) via a mid-line laparotomy and hyperthermic intraperitoneal chemotherapy (HIPEC). CRS comprised of a cervical extirpation, a bilateral salpingoophorectomy and an omentectomy. Additionally, multiple peritoneal biopsies and an abdominal wash cytology was obtained. Intraoperatively there was no macroscopic evidence of disseminated intraperitoneal disease or any residual tissue at time of surgical re-exploration.

Upon completion of CRS, HIPEC was conducted on the closed abdomen by using an automated heat-exchanger perfusion device (Therm-Chem HT 2000). 32.5mg doxorubicin (15mg per m² body surface) were dissolved in 3000ml 0.9% NaCl solution, heated to 42°C and circulated intraabdominally for about 60 minutes with a mean perfusion rate of 2000 milliliters per second, by using an intake catheter placed in the right upper abdomen and two outlet catheters, placed in the left upper abdomen and the pouch of Douglas (ThermaSolutions Procedure Kit).

INCIDENTALLY MORCELLATED HIGH GRADE LEIOMYOSARCOMA TREATED BY CYTOREDUCTIVE SURGERY AND SIMULTANEOUS HYPERTHERMIC INTRAPERITONEAL CHEMOTHERAPY

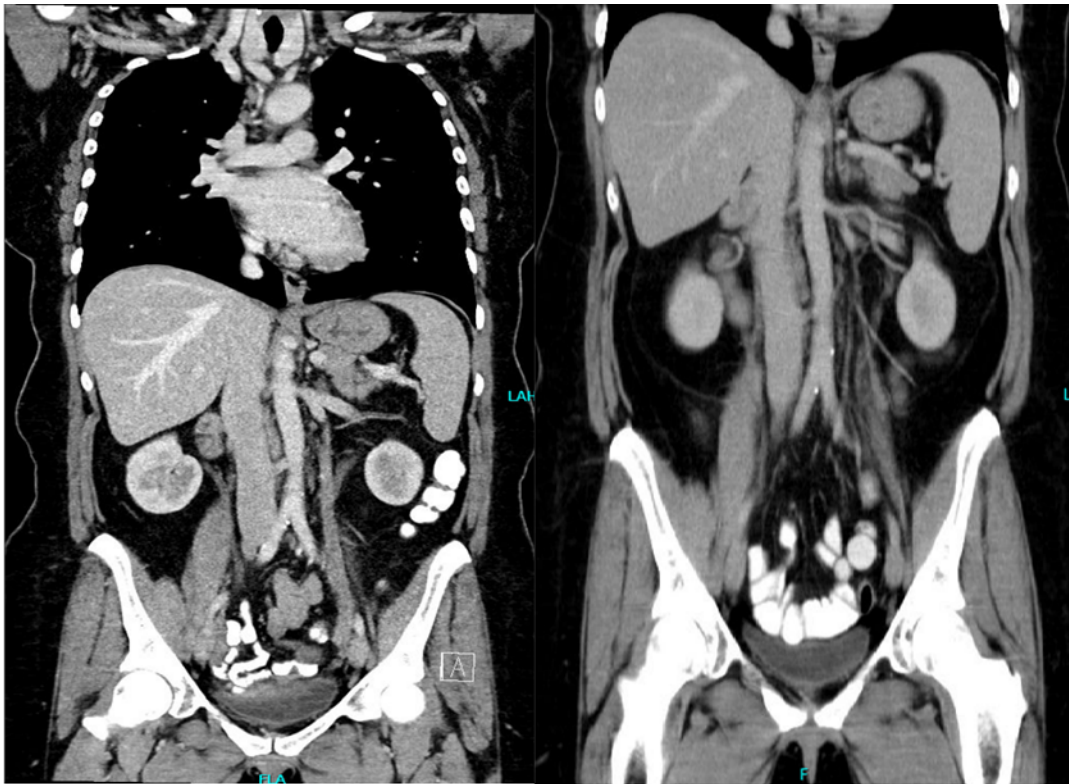


FIGURE 2: Imagistic aspects of the lesion

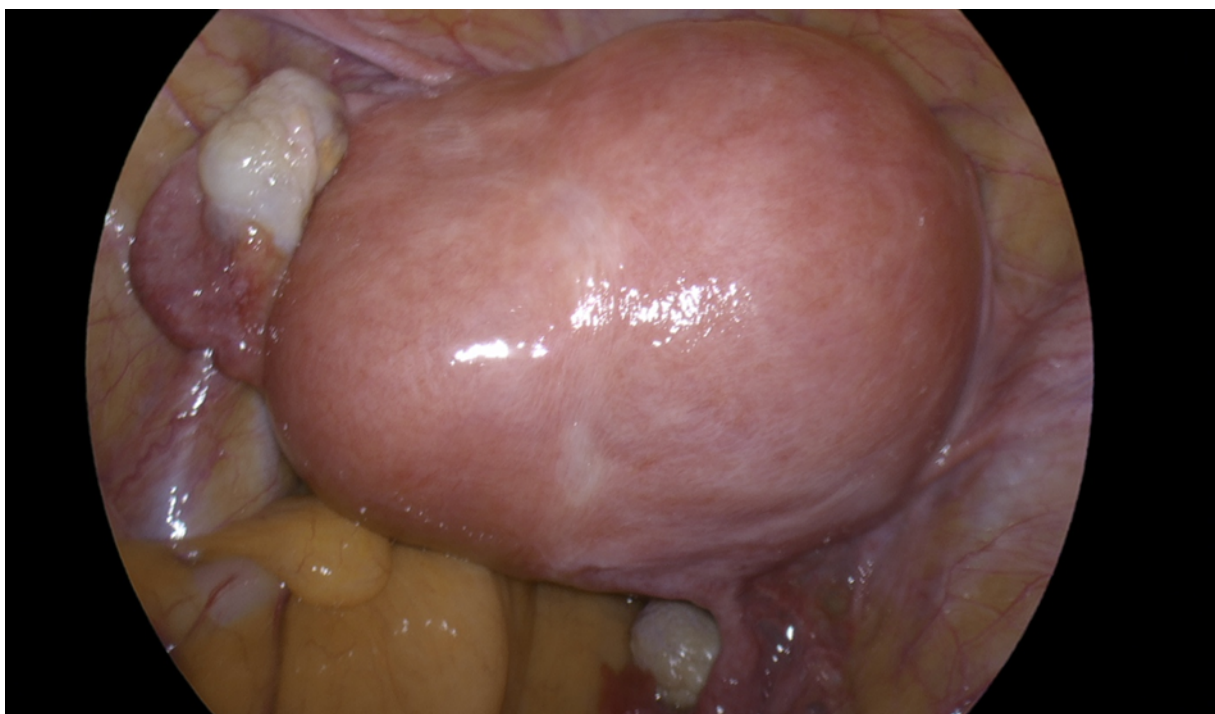


FIGURE 3: Laparoscopic aspect of the lesion

Temperature of the applied HIPEC was constantly measured during the procedure by using thermal probes in the three application catheters. A total operating time of 184 minutes was recorded.

The further postoperative course proved without complications and the patient was discharged from our department on the 12th day after the surgery. No postoperative complication was observed. Upon final pathologic examination the tumor was classified as pT2b, cN0, pM0, R0, G3.

The oncology team recommended adjuvant chemotherapy, but the patient opted against a cytostatic medical treatment. Instead, after discussing *nihil* versus an endocrine treatment as an adjuvant approach, the patient opted for an oral treatment with a selective endocrine receptor modulator. An endocrine therapy that included Tamoxifen (10mg once a day) was hence initiated as adjuvant therapy.

Patient was followed up in our outpatient-department with a gynecological examination and a transvaginal and abdominal ultrasound three and six months postoperatively and an additional computer tomography imaging of the abdomen and the pelvis twelve months postoperatively, each time without clinical or radiologic evidence of recurrent disease.

In a review of the published literature with the help of *Medline* conducted using the search terms “*uterine leiomyosarcoma*”, “*HIPEC*” and “*doxorubicin*”, we did not find any earlier scientific reports about the use of doxorubicin as a single agent in patients undergoing concomitant HIPEC and CRS for morcellated uterine leiomyosarcoma.

3 | DISCUSSION

The matter of dissemination of tumor cells after accidental morcellation of uterine sarcoma, pre- and intraoperatively mistakenly classified as benign fibroids has led to an increase in concerns related to the use of so called power-morcellators during laparoscopic hysterectomy, prompting the FDA to publish a safety communication (6).

As in our patient, in the majority of cases the diagnosis of a leiomyosarcoma is obtained postoperatively in hysterectomies or myomectomies undertaken for a

presumed symptomatic uterine fibroid (7). Although some authors have reported diagnostic algorithms for differentiating between leiomyosarcoma and fibroids preoperatively and hence guide the appropriate usage of power morcellators, the clinical use of these algorithms warrants further studies (8).

Recent retrospective case series have indicated that overall-survival of patients with leiomyosarcoma in whom power morcellators had been accidentally used to extract specimens during laparoscopic myomectomy or hysterectomy might be (3, 9) the optimal further therapeutic management of this group of patients is subject of an ongoing clinical research.

Einstein and colleagues suggested that following an appropriate radiologic workup, surgical restaging of the mass should be offered for patients with subtotal hysterectomy or inadvertently morcellated uterine leiomyosarcomas (10).

Oduyebo et al reported that 28.5% of patients with an inadvertently morcellated uterine leiomyosarcoma experienced an upstaging after surgical exploration despite an unremarkable initial radiologic work-up, stressing out the importance of a surgical completion in such clinical situations (2).

In our patient, we did not encounter any upstaging. In patients with morcellated leiomyosarcoma having undergone CRS, pelvic radiation, as well as conventional, intravenous chemotherapy have been explored as adjuvant treatments (11, 12).

The concept of combining cytoreductive surgery with a concomitant HIPEC therapy as a treatment option for laparoscopic resection of uterine leiomyosarcoma with morcellation has been recently explored by Sugarbaker and colleagues, who applied cytoreductive surgery and a combined HIPEC of doxorubicin and cisplatin in patients with early stage uterine leiomyosarcomas after laparoscopic morcellation. In their study they observed a low intra- and postoperative morbidity rate (13).

In a case series of Baretta and colleagues, the oncologic outcome of 37 patients with CRS and HIPEC for miscellaneous malignant mesenchymal tumors was analyzed (14). Within the subgroup of patients with uterine leiomyosarcomas (N=8), the authors observed a higher proportion of long survivors and

INCIDENTALLY MORCELLATED HIGH GRADE LEIOMYOSARCOMA TREATED BY CYTOREDUCTIVE SURGERY AND SIMULTANEOUS HYPERTHERMIC INTRAPERITONEAL CHEMOTHERAPY

best local-regional-free survival compared to the total study cohort.

To our knowledge, our case-study constitutes the first report of the use of doxorubicin as a single-agent HIPEC in the treatment of patients with morcellated leiomyosarcoma.

We choose to use doxorubicin as a single-agent substance in a HIPEC protocol for the treatment of a morcellated leiomyosarcoma due to the relative safety and tolerance of heated doxorubicin in the context of an intraperitoneal application, which had been previously demonstrated (15).

We did not choose combination chemotherapy for HIPEC in our patient, since we anticipated only minimal residual tumor burden during CRS and hence aimed to limit potential adverse side-effects and morbidity of the systemic therapy.

In our case we observed no post-operative complications and a disease-free survival of more than 18 months. Our case suggests that CRS and concomitant HIPEC might be a clinical valuable approach in the management of patients with morcellated leiomyosarcoma during precedent laparoscopic hysterectomies or myomectomies which merits further exploration. Due to the relatively low incidence of such clinical situations, we presume that it might be a challenging task to obtain data for the optimal adjuvant treatment of patients with morcellated leiomyosarcoma from randomized clinical trials. Hence, case reports and small clinical series could be a valuable addition to increase experience with the therapeutic management of morcellated leiomyosarcomas. (16)

4 | CONCLUSIONS

The incidental morcellation of uterine sarcoma during laparoscopic procedures has recently come into the focus of specialists. The oncologic treatment of such patients constitutes a major clinical challenge for the gynecologic oncologist.

We describe the case of a patient with an incidental morcellation of a high grade uterus sarcoma successfully treated with a Doxorubicin HIPEC in combination with cytoreductive surgery. To the best of

our knowledge our case represents the first scientific evaluation of a single-agent Doxorubicin HIPEC in patients with the diagnosis of a accidentally morcellated sarcoma of the uterus. Hence, we feel that our manuscript might be a helpful contribution in the scientific evaluation of treatment options in this clinical situation.

Consent:

Written informed consent was obtained from the patient for publication of this paper.

Funding:

There has been no financial support for this work.

Abbreviations:

CRS: cytoreductive surgery

HIPEC: hyperthermic intraperitoneal chemotherapy

ULMS: uterine leiomyosarcoma

STUMP: smooth muscle tumor of uncertain malignant potential

WCC: white cell count; CRP: C-reactive protein; CT: computed tomography.

REFERENCES

1. Baird DD, Dunson DB, Hill MC, Cousins D, Schectman JM. High cumulative incidence of uterine leiomyoma in black and white women: ultrasound evidence. *Am J Obstet Gynecol.* 2003 Jan; 188(1):100-7.;
2. Oduyebo T, Rauh-Hain AJ, Meserve EE, Seidman MA, Hinchcliff E, George S, Quade B, Nucci MR, Del Carmen MG, Muto MG. The value of re-exploration in patients with inadvertently morcellated uterine sarcoma. *Gynecol Oncol.* 2014 Feb; 132(2):360-5. doi: 10.1016/j.ygyno.2013.11.024. Epub 2013 Dec 1.;
3. Park JY, Park SK, Kim DY, Kim JH, Kim YM, Kim YT, Nam JH. The impact of tumor morcellation during surgery on the prognosis of patients with apparently early uterine leiomyosarcoma. *Gynecol Oncol.* 2011 Aug; 122(2):255-9. ;.

4. Roque DR, Taylor KN, Palisoul M, Wysham WZ, Milam B, Robison K, Gehrig PA, Raker C, Kim KH. Gemcitabine and Docetaxel Compared With Observation, Radiation, or Other Chemotherapy Regimens as Adjuvant Treatment for Stage I-to-IV Uterine Leiomyosarcoma. *Int J Gynecol Cancer*. 2016 Mar; 26(3):505-11;.
5. Sun, J. H., Z. H. Ji, Y. Yu, H. T. Wu, C. Q. Huang, Q. Zhang, et al. 2016. Cytoreductive surgery plus hyperthermic intraperitoneal chemotherapy to treat advanced/recurrent epithelial ovarian cancer: results from a retrospective study on prospectively established database. *Transl. Oncol*. 9:130-138;.
6. Parker W, Pritts E, Olive D. Risk of morcellation of uterine leiomyosarcomas in laparoscopic supracervical hysterectomy and laparoscopic myomectomy, a retrospective trial including 4791 women. *J Minim Invasive Gynecol*. 2015; 22:696-697;.
7. Parker WH, Kaunitz AM, Pritts EA, et al. U.S. Food and Drug Administration's guidance regarding morcellation of leiomyomas: well intentioned, but is it harmful for women? *Obstet Gynecol*. 2016; 127:18-22;.
8. Nagai, T., Y. Takai, T. Akahori, H. Ishida, T. Hanaoka, T. Uotani, et al. 2015. Highly improved accuracy of the revised PREoperative sarcoma score (rPRESS) in the decision of performing surgery for patients presenting with a uterine mass. *Springerplus* 4:520;.
9. Gao Z, Li L, Meng Y. A Retrospective Analysis of the Impact of Myomectomy on Survival in Uterine Sarcoma. *PLoS One*. 2016;11(2):e0148050. Epub 2016 Feb 1. ;.
10. Einstein MH, Barakat RR, Chi DS, et al. Management of uterine malignancy found incidentally after supracervical hysterectomy or uterine morcellation for presumed benign disease. *Int J Gynecol Cancer* 2008; 18:1065-70;.
11. Reed NS, Mangioni C, Malmstrom H, et al. Phase III randomised study to evaluate the role of adjuvant pelvic radiotherapy in the treatment of uterine sarcomas stages I and II: an European Organisation for Research and Treatment of Cancer Gynaecological Cancer Group Study (protocol 55874). *Eur J Cancer* 2008; 44:808-18;.
12. Hensley ML, Ishill N, Soslow R, et al. Adjuvant gemcitabine plus docetaxel for completely resected stages I-IV high grade uterine leiomyosarcoma: results of a prospective study. *Gynecol Oncol* 2009; 112:563-7;.
13. Sugarbaker P, Ihemelandu C, Bijelic L. Cytoreductive Surgery and HIPEC as a Treatment Option for Laparoscopic Resection of Uterine Leiomyosarcoma with Morcellation: Early Results. *Ann Surg Oncol*. 2016 May; 23(5):1501-7. ;.
14. Baratti D, Pennacchioli E, Kusamura S, et al. Peritoneal sarcomatosis: is there a subset of patients who may benefit from cytoreductive surgery and hyperthermic intraperitoneal chemotherapy? *Ann Surg Oncol*. 2010; 17:3220-8;.
15. Roth L, Eshmuminov D, Laminger F, Koppitsch C, Schneider M, Graf T, Gupta A, Kober F, Roka S, Gertsch P, Lehmann K. Systemic inflammatory response after hyperthermic intraperitoneal chemotherapy (HIPEC): The perfusion protocol matters! *Eur J Surg Oncol*. 2019 Mar 29. ;.
16. Berbec Sorin, Ardeleanu Valeriu, Constantin Vlad Denis, Paunica Ioana and Toma Alexandra. Therapeutic approach for Amyand's hernia; a case report. *Journal of Mind and Medical Sciences: Vol.7 Iss. 1, Article 17*;.

How to cite this article: How to cite this article: Răzvan Petru Derihaci , Hüseyin Cengiz , Shadi Younes , Adriana Florentina Burcea , Anke Mothes , Julia Radosa , Bernd Reith , Nadja Dornhöfer , Alexandru Nechifor and Marc Radosa, ***Incidentally Morcellated High grade Leiomyosarcoma Treated by Cytoreductive Surgery and simultaneous Hyperthermic Intraperitoneal Chemotherapy.** *Journal of Medical Case Reports and Reviews*. 2022;1061-1067.
<https://doi.org/10.52845/JMCRR/2022/5-1-3>