



## STRESS RELATED ORAL HABITS: TWO CASE REPORTS

Aybike Şeker<sup>1</sup>, Mert Çelik<sup>1</sup>, Aykut Kanat<sup>2</sup>

<sup>1</sup>Istanbul Medipol University

<sup>2</sup>Endodontic Specialist in Istanbul

---

### Article Info

---

**\*Corresponding Author:**

Dt.Aybike Şeker

---

---

### Abstract

---

**Objectives:** Although bad mouth habits can be seen at almost any age, it is a condition that temporarily or permanently damages the teeth and mouth tissues, especially for children if precautions aren't taken. It is seen in children due to many reasons. In this case report, it is aimed to present 2 patients with stress related bad mouth habit.

**Case report:** Extraoral and intraoral findings are presented in two 9 year old patients who have the habit of biting their cheek and have self-mutilation habit in oral tissues due to stress. The patients were checked 6 months after the psychiatric treatment and it was observed that they recovered completely.

**Conclusion:** Although it is easier to treat bad mouth habits diagnosed in the early period, the application of dental treatment after psychiatric treatment is a better choice in the treatment of stress-induced habits.

**Key words:** Cheek Biting, Oral Habits, Pediatric Dentistry, Self Mutilation .

---

### Introduction:

Bad mouth habits are defined as psychological origin habits that people apply to their own teeth, soft and supportive tissues temporarily or permanently (1-3). When it is not left or treated at a certain age in children, it can cause malocclusions in the teeth and defects in the mouth. Children may have some oral habits that can be temporarily or permanently harmful to teeth and support soft tissues. These are thumb and finger sucking, lip and cheek biting, infancy swallowing-tongue pushing, nail eating, tooth

tightening, grinding and mouth breathing. Many of these habits are often unnoticed or considered unimportant by parents (4).

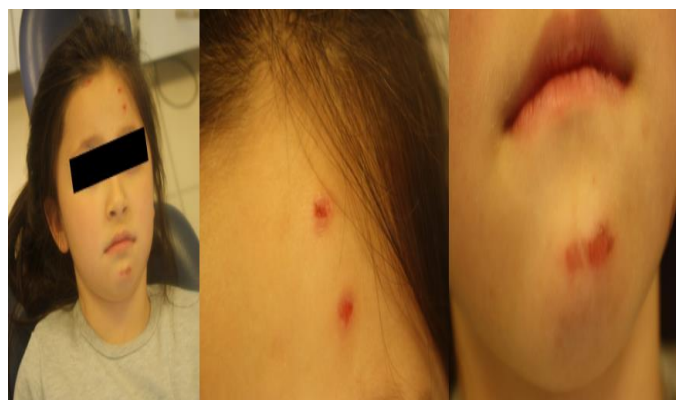Pleasure habits that are not emotionally long-lasting are generally not harmful to the person. These habits are considered as a way of escaping from the tension that may develop in the person until the symptoms of anxiety occur. Such habits can be seen in adults as well as in children (4). Bad mouth habits are reported as movements learned with muscle contractions.

Abnormal habits can negatively affect facial development (3). While there are factors such as emotional causes and stress among the causes of these habits, high restorations and closing problems can also cause bad mouth habits (3). In this case report, it is aimed to share intraoral and extraoral findings of two children with self-injury and cheek-biting habit.

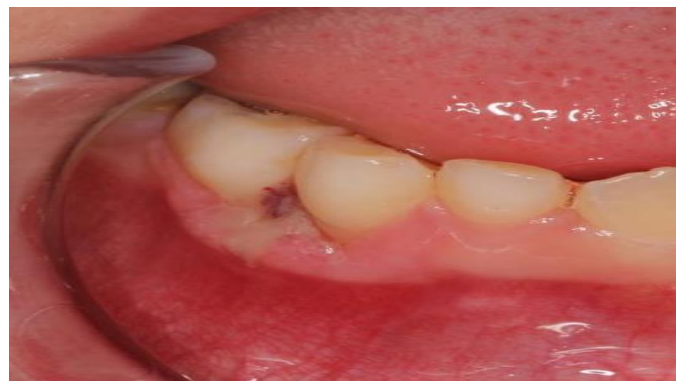**Case reports:**

**Case report 1:**

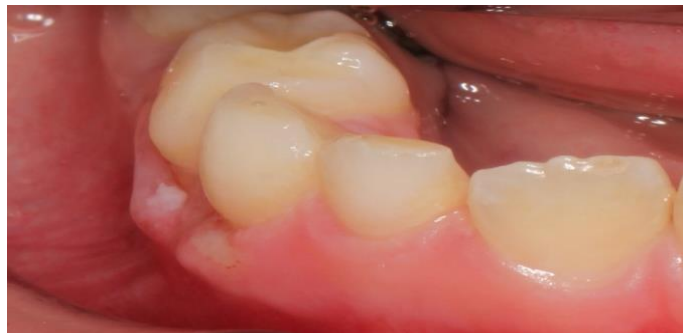9-year-old girl admitted to the clinic with the complaint of gingival recessions showed marked skin picking on the left side of the face and tip of the chin (fig.1) and irritation due to trauma in the area of the right first deciduous molar and deciduous canine in the lower jaw (fig.2). It was determined that the child lost his mother about 6 months ago, and therefore hurt herself. Fluor varnish (MI Varnish, GC Corp., Japan) was applied to the relevant teeth and the child was directed to the child psychiatric service. When the patient came for control 6 months after the psychiatric treatment, it was observed that the surrounding tissues where the habit was abandoned started to heal (Fig.3).



**Fig. 1: Extraoral view of the patient**



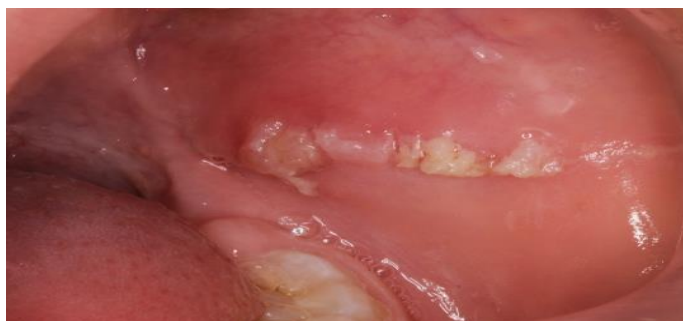**Fig. 2: Intraoral view of the patient**



**Fig. 3: View after 6 months**

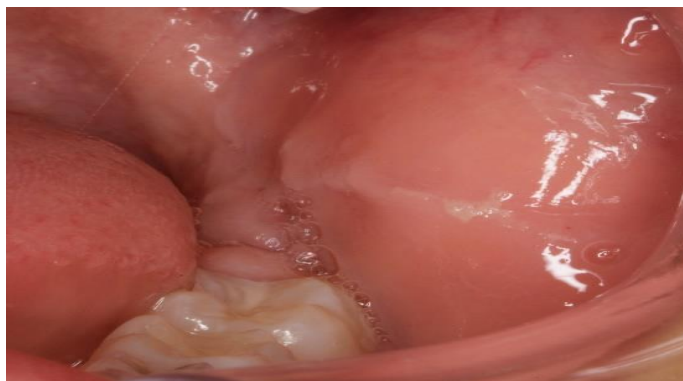
**Case report 2:**

In the examination of a 9-year-old girl who applied to the clinic due to the formation of leukoplakia in the cheek, a hyperkeratotic lesion was detected due to biting her cheek in the buccal region on the left side of the patient (fig.4). It was decided to send the patient to the pediatric psychiatry service and apply treatment according to the result, considering that a situation that could cause this issue could not be detected in the mouth.



**Fig. 4: Hyperkeratotic lesion due to cheek bite**

After the consultation with the pediatric psychiatric service, it was determined that the patient was biting her cheek due to stress. After psychiatric treatment, the patient was directed for removing the lesion surgically. In the control performed 6 months later, it was observed that the patient recovered (Fig.5).



**Fig. 5: View after 6 months**

## Discussion:

Self-injurious behavior is generally defined as behaviors that seriously harm body tissues without intentionally aiming for death (5). Self-injury is a self-help behavior that provides a quick but temporary solution to get rid of depersonalization, guilt, feelings of rejection, hallucinations, sexual issues and complex emotions (6). Inadequate parental care, especially maternal deprivation, is reported to be behind self-mutilating behaviors in humans, which can be considered as isolation in a sense.

It is known that psychological factors play a big role in the etiology of habit of harming oneself (mouth tissues) (8). Therefore, it was thought that it would be more accurate for the patient to receive psychological treatment firstly.

Cheek bite (*morsicatio buccarum*) is a condition defined as the bite of the buccal mucosa of a cheek in the form of a chronic habit (9,10). Malocclusions, sharp teeth, stress and the persistence of third molar teeth can be counted among the main causes of chronic cheek bite (11). Due to the chronic cheek biting, lesions may develop on the mucosa, at the level of the occlusion plane, or slightly below hyperkeratotic and locally scattered (9-11). Lip and cheek bites can cause permanent malocclusion. However, although whether these habits produce a malocclusion is still an unanswered and discussed topic (12), in this case it is possible that malocclusion occurs due to repeated bites.

There are different methods to prevent chronic cheek bites. Correction of malocclusions that may cause chronic bite, reducing the sharpness of the sharp teeth by molding them, pulling the third molar teeth and correcting the wrong prostheses are among the treatments aimed at eliminating the causes (8,13,14). The use of psychiatric treatment, medication, or use of occlusion splints are some of the treatment options in the prevention of chronic bite caused by constant teeth-clenching due to stress (15). Apart from these, making a dental supported prosthesis with an acrylic extension in the buccal region where there is a chronic cheek bite is also among the treatment

options. Thanks to this prosthesis, the cheek bite of the patient and the discomfort caused by the patient's cheek bite is prevented (10,16-18). In cases where there is no change in the tooth array yet, it can be considered to apply no treatment and rely on the natural process (12). In the treatment of habits, age, communication with parents and the size of the deformation are influential. The child should be big enough to understand the cause of the treatment (7 at least), have a desire to perceive the importance of the problem and help the treatment process. It is very important that the child who accepts the treatment receives support and encouragement from his parents during the treatment. Although the physician has clinical experience and foresight that can determine the magnitude and degree of deformation, the patient and physician must have prepared themselves for long-term treatment (3). What should never be forgotten in order for the treatment of bad mouth habits to be successful is that the child should really want to give up the habit (12). Nevertheless, as behavioral orientation problems can also be seen in these children, for disabled children who are in need of special healthcare and children who need intensive care, general anesthesia should be evaluated to complete the dental treatment in a single session, for it is an efficient and productive way for providing dental treatment.

## References:

- [1.] 1. Andrija B, Vucicevic-Boras V, Miletic I, Bozic D, Vukelja M. Incidence of oral habits in children with mixed dentition. *Journal of Oral Rehabilitation* 2002;29: 902-905.
- [2.] 2. Bosnjak A, Vucicevic V, Miletic I, Bozic D, Vukelja M. Incidence of oral habits in children with mixed dentition. *Journal of Oral Rehabilitation* 2002;29:902-905.
- [3.] 3. Pinkham JR. *Pediatric Dentistry*. 3rd edn. Iowa: W.B. Saunders Company. 1997;393-401.
- [4.] 4. Castello PM, Gaviao MBD, Pereira LJ, Bonjardim LR. Relationship between oral parafunctional/nutritive sucking habits and temporomandibular joint dysfunction in

- primary dentition. *International Journal of Pediatric Dentistry* 2005; 15: 29-36.
- [5.] 5. Feldman MD. The challenge of self-mutilation: a review. *Compr Psychiatry* 1988;29:252-269.
- [6.] 6. Favazza AR. The coming age of self-mutilation. *J Nerv Ment Dis* 1998;186:259-268.
- [7.] 7. Dallam SC. The identification and management of selfmutilating patients in primary care. *Nurse Pract* 1997;22:159-165.
- [8.] 8. Nurko C, Errington B, Ben Taylor W, Henry R. Lip biting in a patient with Chiari type II malformation: case report. *Pediatr Dent* 1999;21(3):209-12.
- [9.] 9. Shafer H. Diseases of the periodontium. In: Shafer WG, Hine MK, Levy BM, Rajendran R, Sivapathasundharam B, eds. *Shafer's Textbook of Oral Pathology*. 5th ed. New Delhi: Elsevier; 2006. p.404-7.
- [10.] 10. Mohamed K, Kumar VA, Padmanabhan T, Deora N, Mohan S. Cheek bumper prosthesis for a patient with a neurofibromatous lesion in the left cheek. *J Prosthodontics* 2012;21(6):482-6.
- [11.] 11. Ghom A, Ghom S. Oral premalignant lesions and conditions. In: Ghom AG, ed. *Textbook of Oral Medicine*. 1st ed. New Delhi: Jaypee Brothers; 2010. p.171-5.
- [12.] 12. Restrepo CC, Alvarez E, Jaramillo C, Velez C, Valencia I. Effects of psychological techniques on bruxism in children with primary teeth. *Journal of Oral Rehabilitation* 2001; 28: 354-360.
- [13.] 13. Millwood J, Fiske J. Lip-biting in patients with profound neuro-disability. *Dental Update* 2001;28(2):105-8.
- [14.] 14. Walker RS, Rogers WA. Modified maxillary occlusal splint for prevention of cheek biting: a clinical report. *J Prosthet Dent* 1992;67(5):581-2.
- [15.] 15. Chen LR, Liu JF. Successful treatment of selfinflicted oral mutilation using an acrylic splint retained by a head gear. *Pediatr Dent* 1996;18(5):408-10.
- [16.] 16. Mukohyama H, Kadota C, Ohyama T, Taniguchi H. Lip plumper prosthesis for a patient with a marginal mandibulectomy: a clinical report. *J Prosthet Dent* 2004;92(1):23-6.
- [17.] 17. Romero M, Vicente A, Bravo LA. Prevention of habitual cheek biting: a case report. *Special Care Dentist* 2005;25(4):214-6.
- [18.] 18. Silva DR, da Fonseca MA. Self-injurious behavior as a challenge for the dental practice: a case report. *Pediatr Dent* 2003;25(1):62-6.
- [19.] 19. Özükoç C, Kanat A. Analysis of Pediatric Dentistry Patients Treated Under General Anesthesia. *Ann. Int. Med. Den. Res* 2019;5(5):DE46-DE50.