

DELAYED DISLOCATION OF IOL: OCCULT INTRAOCULAR FOREIGN BODY OR TRAUMA CAN BE THE REASON

Dr. Sanjoy Chowdhury*,¹ Dr. Madhumita Srivastava,² & Dr. Nilanjan Chowdhury^{3*}

1 Director Medical and Health Services, Bokaro General Hospital, Jharkhand, Ph no: 8986872947

2 Specialist, Bokaro General Hospital, Jharkhand, 8986873108

3 Postgraduate Resident ophthalmologist, Bokaro General Hospital, Jharkhand

Abstract:

Delayed dislocation of an IOL is a complication which cannot be prevented or predicted but may cause profound visual loss in a good pseudophakic eye.

AIM: To analyse risk factors associated with all the cases of delayed dislocation of IOLs.

METHODS: Hospital based prospective intervention study during 2003-2018. All cases of dislocated IOLs were included. Cases with history of surgical complications were excluded. Routine investigations with MRI were done. Multivariate analysis to detect risk factors was done.

RESULTS: Out of 25 cases 3 cases with h/o PCR were excluded. Mean age: 63.2 years, male: female ratio :5:1. Mean interval: 6.5 years. 12 cases of Iris claw lens dislocated in AC, 3 cases of PCIOL with IOFB detected on MRI, 5 cases of trauma with perfect capsulorrhexis, 2 cases of pseudo exfoliation, 2 cases had longer axial length (>26mm). Multivariate analysis confirmed occult IOFB and trauma as risk factor.

CONCLUSION: Occult IOFB and trauma can lead to delayed dislocation of IOL.

Keywords: Dislocated IOL, Trauma, Foreign body

Corresponding Author: Dr. Sanjoy Chowdhury Director Medical and Health Services, Bokaro General Hospital, Jharkhand, Ph no: 8986872947

Introduction:

Dislocation of IOL is one of the serious complications after cataract surgery. It's a delayed complication that is presented after months or years which can take cataract surgeons by surprise-spontaneous IOL dislocation years

after the original surgery. For many ophthalmologists, the problem comes out of the blue, as the surgery had gone uneventful. The patient will experience blurring of vision as they are not looking through the centre of the IOL anymore while some may actually see the edge of the dislocated IOL. [1] There can be diplopia as well. Patients naturally get very anxious and it

may lead even the surgeon to press the ‘panic button. Zonular dialysis is one of the thoughts that comes to the mind and the surgeon starts to find the reason behind it to be presented so late. Detailed history of patient after the surgery is taken, looking for any possible reasons like trauma. [2] Trauma is one of the most common causes behind IOL dislocation and when patient recalls, it is easier to take that as a major factor for this presentation. But the scenario might not be straight forward every time! One such condition is occult intraocular foreign body. It could have gone into patients’ eye with minimal entry port and not much of a sign of damage of external serous coats especially conjunctiva. Here patient presents with less inflammation than expected. Small sharp objects can get inside eye with great velocity in workers of metal industry. So, there can be relief after inflammation subsides and the incidence is forgotten thereafter, so much that it might not be mentioned when asked about the history of trauma. It is obvious to expect men to be victim of intraocular foreign body more than women, as most of the patients are the workers and the labourers. Meanwhile the foreign body is settled inside the eye and chronic inflammation & subsequent fibrosis sets in. The location of the foreign body will decide the further course of its complications. If the foreign body is located anywhere near the IOL, the fibrosis will cause tractional force & lead to dislocation of IOL. [3]

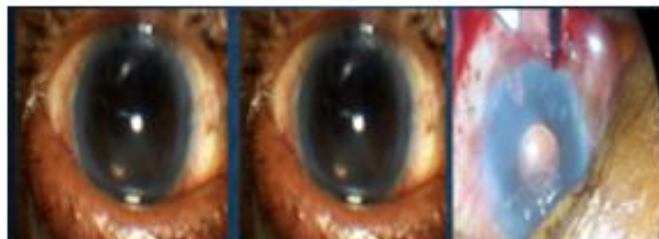
Materials & Methods:

This is a retrospective study performed at the department of ophthalmology, Bokaro General Hospital, Bokaro Steel City, Jharkhand. All the patients presenting with delayed dislocation of IOL operated between years 2003 - 2018 were included in the study.

Exclusion Criteria:

1. Patients presenting less than 1 month of surgery.
2. Intraoperative complications of any kind i.e. Raised IOP, Vitreous loss.
3. Postoperative complications of any kind i.e. Hyphema, TASS.
4. H/o surgical or laser intraocular intervention i.e. PCR

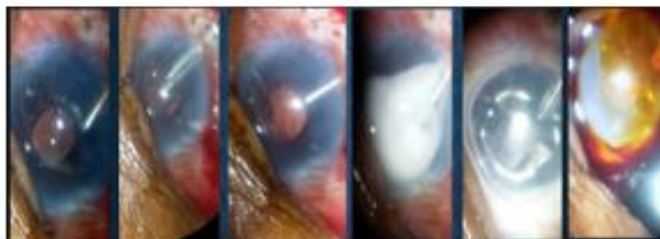Detailed history of ocular as well as systemic diseases was taken. Visual acuity was noted with full correction. Slit lamp examination was performed. IOP was measured by applanation tonometer. Fundus examination was done by indirect ophthalmoscopy and slit lamp bio microscopy with 90 D. Every patient then underwent B scan ocular ultrasonography. Routine investigations of blood and X-ray chest were done. It was followed by MRI (orbit).



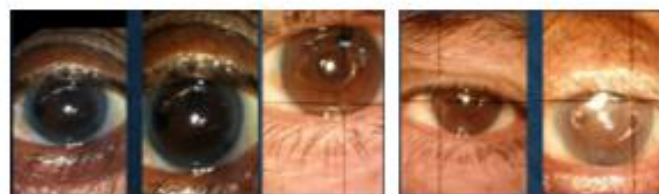Dislocated ICIOL (Nasal clip)



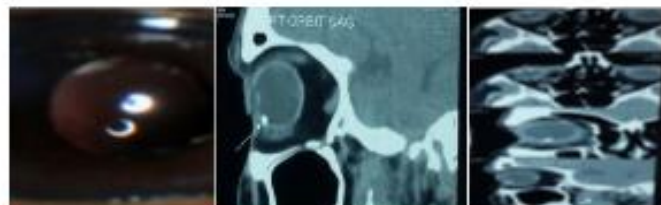
Removed ICIOL: widening of iris clip



Steps of refixation of ICIOL



Refixated ICIOL



Retained IOFB causing dislocation of IOL after 8 years

Results:

Mean age of the patients was 63.2 years.

Male: female ratio was 4.5:1. (18 M: 04 F)

Mean interval of presentation after surgery was found to be 6.5 years.

12 of the total patients were implanted Iris Claw Lens. i.e. 12/22 (54.5 %)

5 of the total patients had history of trauma. i.e. 5/22 (22.72)

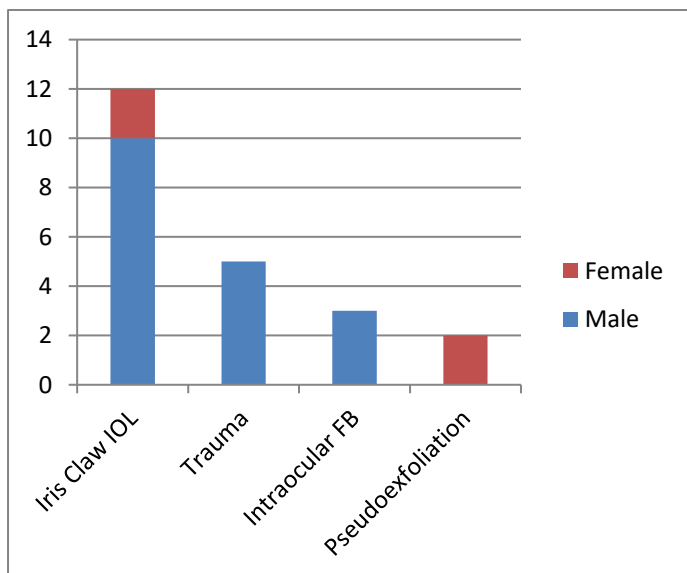
3 of the total patients had occult intraocular foreign body, i.e. 3/22 (13.63)

2 of the total patients had pseudo exfoliation syndrome i.e. 2/22 (9 %)

Distribution of causes of IOL dislocation according to sex:

SEX	Iris Claw Lens	Trauma	Intraocular FB	Pseudo exfoliation
MALE	10	05	03	-
FEMALE	02	-	-	02

Graphical representation of distribution of patients according to the causes:



Chi-Square Calculator

The contingency table below provides the following information: the observed cell totals, (the expected cell totals) and [the chi-square statistic for each cell].

Results					
	ICL	TRM	IFB	PEX	Row Totals
M	10 (9.82) [0.0]	5 (4.09) [0.20]	3 (2.45) [0.12]	0 (1.64) [1.64]	18
F	2 (2.18) [0.02]	0 (0.91) [0.91]	0 (0.55) [0.55]	2 (0.36) [7.36]	4
Column Totals	12	5	3	2	22 (Grand Total)

The chi-square statistic is 10.7963. The P-Value is 0.01288. The result is significant at $p < 0.05$.

Table value of chi-square with degrees of freedom $(2-1)(4-1)=3$ at 0.05 level of significance = 7.81.

Since the calculated value of chi-square is greater than the table value, the hypothesis that there is no association between sex and the causes is rejected. Therefore, we conclude that there is a strong association between sex and the causes.

Discussion:

When a case of dislocation of IOL comes to the ophthalmologist months or years after the surgery, history taking becomes one of the key steps to come to the diagnosis.^[4] In our study, we tried to find out the possible causes for delayed dislocation of IOL. More than half of the patients (i.e.54.5%) had Iris Claw -IOL implanted suggesting that the type of implanted lens has got significant influence this outcome as, no other cause was identified in these patients. Both the patients, in which axial length was found to be > 26 mm, had Iris Claw - IOL implanted in them. All the patients with history of trauma and occult intraocular FB were male workers & labourers. These patients are always at risk as a part of professional hazards and thorough imaging should be integral part in work up of these cases. In the statistical analysis, we found strong association between sex of the patient and the cause behind the dislocated IOL. It was due to the fact that male workers are naturally exposed to trauma at work or entry of foreign body inside the eye through penetrating wound. Thus here was gender predilection for these causes. If the

treating ophthalmologist keep this in mind, it would be easier to reach to possible causes. Also it throws light on the need of proper protective measures for the industrial workers at their place of work.

Conclusion:

Before implanting iris claw lens for refractive procedure it should be judiciously judged as this lens is most commonly dislocated. Also occult IOFB and trauma can cause delayed dislocation of IOL. In vivo studies are required for measurement of zonular strength. Evaluating meticulously host-environment factor will not let the paradise to be lost.

References:

[1.] S L Pueringer, D O Hodge, J C Erie. Risk of Late Intraocular Lens Dislocation after

Cataract Surgery, 1980-2009: A Population-Based Study. *Am J Ophthalmol* 2011;152:618-623

[2.] Shingleton BJ, Yang Y, O'Donoghue MW. Management and outcomes of intraocular lens dislocation in patients with pseudo exfoliation. *J Cataract Refract Surg* 2013; 39: 984-93.

[3.] Hayashi K, Hirata A, Hayashi H. Possible predisposing factors for in-the-bag and out-of-the bag intraocular lens dislocation and outcomes of intraocular lens exchange surgery. *Ophthalmology* 2007; 114:969-75.

[4.] Monestram EI. Incidence of dislocation of intraocular lenses and pseudophakodonesis 10 years after cataract surgery. *Ophthalmology* 2009; 116:2315-320.