



## CASE REPORT

### Tubercular Splenic Abscess with Gastrointestinal Tuberculosis in an Immunocompetent Child: A Rare Case Report

Dr. Tarun Singh <sup>1\*</sup> | Dr. Chirag Sundesha DNB Resident<sup>2</sup> | Dr. Deepak Gupta, Senior Consultant Pediatrics<sup>2</sup> | Dr. Mukesh Yadav, Senior Consultant Pediatrics<sup>2</sup> | Dr. Anju Bhatia, Senior Consultant Radiology<sup>2</sup> | Dr. N. K. Sharma, Director and chief Radiologist<sup>3</sup> | Dr. Ajay Kumar, DNB Resident<sup>2</sup>

<sup>1</sup>Department of Pediatrics, Venkateshwar Hospital, Dwarka, New Delhi

<sup>2</sup>Department of Pediatrics, Sanjay Gandhi Memorial Hospital, New Delhi

<sup>3</sup>National MRI Scan Centre, Punjabi Bagh, New Delhi

#### Abstract

**Background :** Tuberculosis (TB) is a major health problem in India. Tuberculosis is a lethal infectious disease that still remains a major threat in developing countries. TB manifests with diverse clinical symptoms most commonly as pulmonary TB. Splenic TB usually occurs as a part of miliary TB in immunocompromised patients and rarely as an isolated splenic TB in an immunocompetent individual. Patients susceptible to acquiring splenic tuberculosis usually have some risk factors such as immunosuppression, pyogenic infections, splenic abnormalities, prior trauma to spleen and sickle cell disease. We have reported a rare case of 11 year boy who presented with tubercular splenic abscess along with features of gastrointestinal tuberculosis.

**Keywords:** Splenic Tuberculosis, immunocompetent, gastrointestinal, splenic abscess, child

Copyright : © 2021 The Authors. Published by Publisher. This is an open access article under the CC BY-NC-ND license (<https://creativecommons.org/licenses/by-nc-nd/4.0/>).

## 1 | INTRODUCTION

**T**uberculosis (TB) is a lethal infectious disease that still remains a major threat in developing

countries. (1) (2) (3) Tuberculosis is a major health problem in India. TB manifests with diverse clinical symptoms most commonly as pulmonary TB. Splenic TB usually occurs as a part of military TB in

immunocompromised patients and very rarely as an isolated splenic TB in an immunocompetent individual. (1) (2) Spleen is the third most common organ involved (75%) in miliary TB after lung (100%) and liver(82%). (3) Despite medical improvement in the diagnosis and treatment of infectious

diseases over the years, tuberculosis continues to be a major health problem in developing countries.

There are few cases of solitary splenic tuberculosis reported in the literature internationally, especially single large mass-forming splenic tuberculosis. (2) (4) Splenic tuberculosis is extremely rare. (1)

Approximately 15–20 % of all cases of tuberculosis are extrapulmonary; of these 3–11 % are abdominal. Splenic tuberculosis is very unusual with only a few case reports. In a series evaluated retrospectively, the rate of splenic tuberculosis was reported as 8 %, while in the literature the rate of micronodular type of involvement was reported at around 5 %. Splenic tuberculosis presents with diverse clinical symptoms. The most common symptoms reported of splenic TB are fever (82.3 %),

fatigue, weight loss (44.12 %), and splenomegaly (13.2–100 %). (4) Splenic TB often poses diagnostic

complexity and therefore, it is likely to be misdiagnosed as splenic malignancy, metastases, lymphoma, hemangioma, or splenic abscess. (2) (4) The misdiagnosis rate is high if there is no tuberculosis history in any other organs. To the best of our knowledge, very few cases of tubercular splenic abscess have been reported in pediatric age group in India.

**Supplementary information** The online version of this article (<https://doi.org/xx.xxx/xxx.xx>) contains supplementary material, which is available to authorized users.

**Corresponding Author:** *Dr. Tarun Singh*  
Department of Pediatrics, Venkateshwar Hospital,  
Dwarka, New Delhi

## 2 | CASE PRESENTATION

A 11-year-old boy presented with complaints of high-grade fever and left upper abdominal pain for

last 3 weeks. There was history suggestive of loss of appetite and anorexia. There was no history of trauma and contact with a tuberculous patient. On examination, the patient was febrile with a temperature of 39.4°C; pallor was present and there was no lymphadenopathy. Abdominal examination showed a palpable spleen of about 2 cm below the left costal margin. Rest of the systemic examination was normal. The patient was admitted for further evaluation.

Blood investigations showed haemoglobin of 9g/dL, erythrocyte sedimentation rate (ESR) of 30 mm in the first hour, the total leucocyte count was 6.80 x 10<sup>3</sup> cells/ cubic millimeter and platelet count was within normal limits. Evaluation of anaemia using peripheral smear showed normocytic

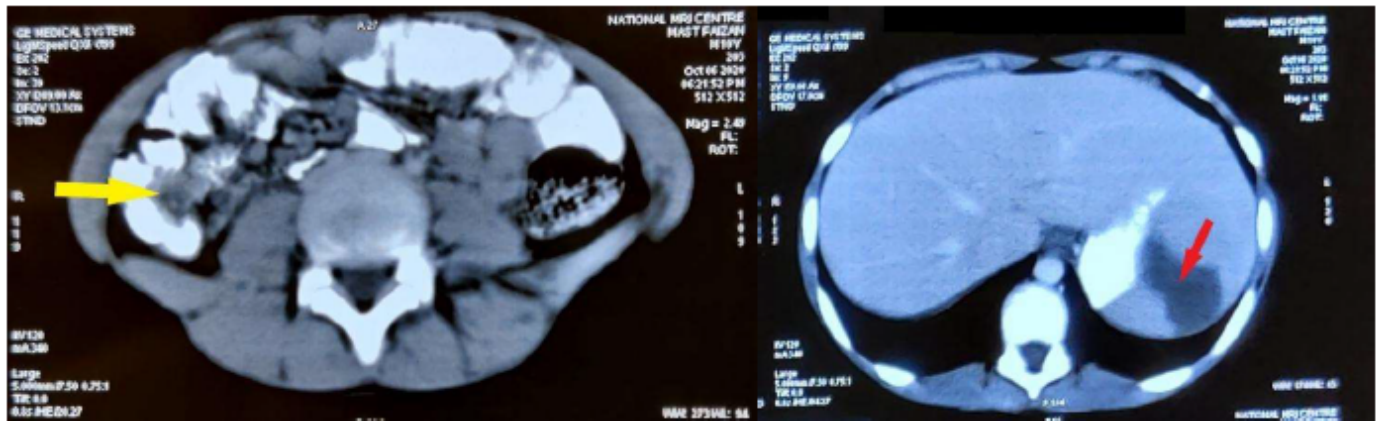
normochromic blood picture and iron profile was suggestive of anaemia of chronic disease. Liver function, renal function, serum electrolytes, random blood glucose, serum amylase and lipase were normal. HIV antibody testing was carried out and the report was negative. Chest radiograph was done for focus of tuberculosis but it was normal. His Montoux test and gene-Xpert were negative. Stool

sample report was negative for worms, ova, cysts and parasites. Ultrasonography of the Abdomen showed the enlarged spleen with a large hypoechoic lesion measuring 4.8x 3.5cm.

Contrast-enhanced CT (CECT) abdomen showed multiple varying size hypodense lesions (largest lesion measuring 4.8x2.6cm) involving the splenic parenchyma suggestive of splenic abscess with finding of multiple mesenteric lymph nodes, inflammatory bowel wall thickening involving the terminal ileum, ileo-caecal region and caecum. Figure 1

Because of the radiological picture of CECT Abdomen, patient was clinically diagnosed as a case of tubercular splenic abscess with gastrointestinal tract tuberculosis. Fine needle aspiration cytology

# TUBERCULAR SPLENIC ABSCESS WITH GASTROINTESTINAL TUBERCULOSIS IN AN IMMUNOCOMPETENT CHILD: A RARE CASE REPORT



**FIGURE 1:** Axial CT cut reveals bowel wall thickening involving the terminal ileum, ileo-caecal region and caecum (Yellow arrow) with multiple varying sized hypodense lesion involving spleen (Red arrow).

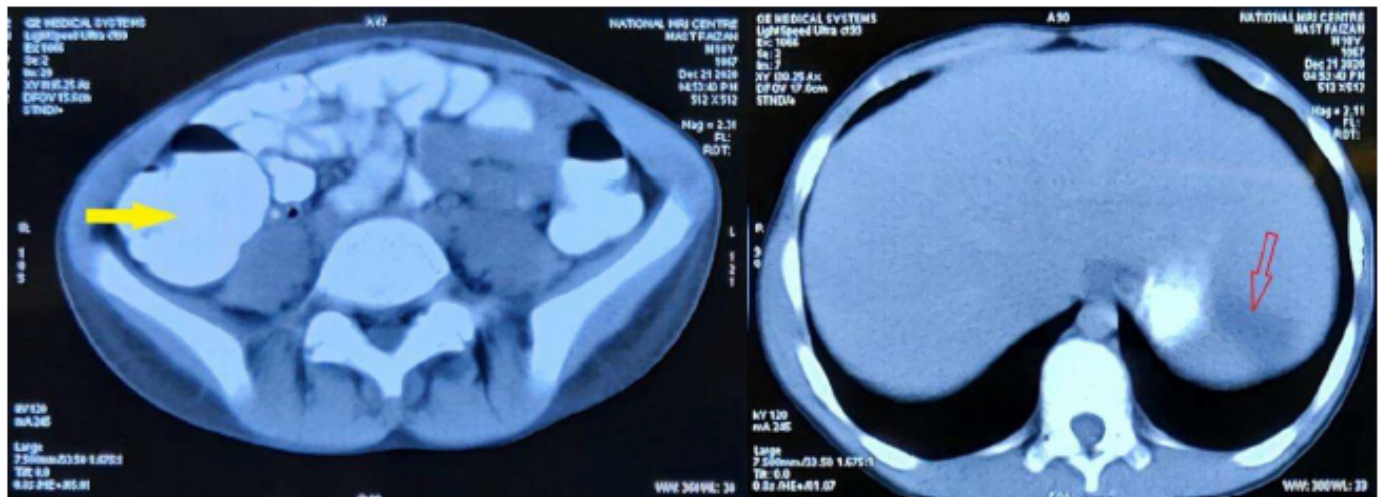
(FNAC) and core needle biopsy (CNB) were not performed because of a potential risk of rupture. The child was started on antituberculosis drugs (ATT) as per revised national tuberculosis control programme (RNTCP). The child was called back after 10 weeks of ATT. At this time the child was asymptomatic and on follow up scan. CECT Abdomen Figure 2 showed marked resolution of splenic lesion, mesenteric lymph nodes and bowel wall thickening as compared to previous scan. Hence, we confirmed that initial lesion in the spleen was splenic tubercular abscess which showed marked resolution after 10 weeks of ATT.

### 3 | DIFFERENTIAL DIAGNOSIS

- Splenic Tuberculosis
- Splenic abscess
- Hydatid cyst of the spleen
- Pseudocyst of the spleen
- Lymphoma of the spleen
- Metastasis to spleen

### 4 | DISCUSSION

Primary splenic tuberculosis is an unusual presentation which is commonly seen in immunocompromised individuals and a rare presentation in immunocompetent host. (1, 2, 4) In our case, patient was immunocompetent as he had no history of previous hospitalizations or repeated infections. His mantoux test and gene Xpert were reported negative. As in case report of Metlo A. et al, their patient also reported negative for above mentioned tests. (1) Despite this, patient presented with abdominal tuberculosis leading to splenic tubercular abscess and gastrointestinal involvement. However, there is no strict pattern of presentation of the disease and various presentations could be possible ranging from primary tubercular lesion of spleen or as a part of miliary tuberculosis without any findings in lungs. Diagnosis of splenic tuberculosis is usually delayed because of non specific symptoms. (1, 2, 5) Nearly half of the cases of splenic tuberculosis is associated with abscess formation due to over reaction of host immune response, in which they could even present with fever, chills, left upper quadrant abdominal tenderness associated with splenomegaly. (3, 6) In a case report by Basa JV. et al, pain is reported as uncommon symptom while more common symptoms includes fever followed by fatigue



**FIGURE 2:** Axial CT cuts demonstrate decrease in size of bowel wall thickening as compared to previous scan (Yellow arrow) and marked resolution in hypodensity of splenic lesion (Red arrow).

with weight loss and splenomegaly (7) Our case also presented with fever, pain in left upper quadrant and splenomegaly on clinical examination. Splenic tuberculosis could be associated commonly with leucopenia with anemia which could be microcytic or normocytic. (1, 7) Our patient was also found to have normocytic normochromic anemia. Imaging studies including USG abdomen and CT scan helps in confirming clinical findings as well as in establishing diagnosis with type of lesion involved. (1, 3) They have been specifically found to be

more sensitive in diagnosing splenic abscess. (1) Different presentations could be formation of single or multiple hypoechoic focal lesions, granulomas, calcifications in spleen, space occupying lesion or isolated splenomegaly. (2, 4–6) In our case, USG whole abdomen reported to have splenic lesion measuring 5.8 cm x 7.5 cm in initial report and CT reveals presence of multiple hypodense lesions in splenic parenchyma, largest measuring 48 x 26 mm with slight irregularities in splenic margins. Repeat USG and CT scan after treatment of 10 weeks showed marked improvements in lesions. Gold standard method for confirming splenic tuberculosis is splenectomy with biopsies. For histopathologic diagnosis, the role of fine needle aspiration cytology (FNAC) and core needle biopsy (CNB) is debatable and not well established. (1) In our case, this was not performed due to risk of rupture and

bleeding.

Similar to that of pulmonary tuberculosis, splenic lesions are also treated with regular and proper administration of Anti Tubercular Therapy (ATT). Sometimes, it is being augmented with splenectomy. In our case also, marked clinical and radiological improvement was seen after 10 weeks of ATT.

## 5 | CONCLUSIONS

Splenic tuberculosis is a rare disorder, especially in immunocompetent child. According to World Health Organization, in 2019, TB is one of the top 10 causes of death and 1.2 million children fell ill with TB globally and the 30 high TB burden countries accounted for 87% of new cases. Eight

countries account for two thirds of the total, with India leading the count, followed by Indonesia, China, the Philippines, Pakistan, Nigeria, Bangladesh and South Africa.

In conclusion, we have reported here an extremely rare case of tubercular splenic abscess with gastrointestinal TB in an immunocompetent child, who showed marked clinical improvement and marked resolution of radiological picture of gastrointestinal and splenic tuberculosis with early start of ATT, thus avoiding the need of any surgical intervention.

## 6 DECLARATION OF PATIENT CONSENT

The authors certify that they have obtained all appropriate patient consent forms. In the form the patient has given his consent for his images and other clinical information to be reported in the journal. The patient understands that his name and initials will not be published and due efforts will be made to conceal his identity, but anonymity cannot be guaranteed.

### Financial support and sponsorship:

Nil.

### Conflicts of interest:

There are no conflicts of interest.

## REFERENCES

1. Kumar A, Kapoor VK et al; Splenic tuberculosis in an immunocompetent patient can be managed conservatively: a case report; *Gastroenterology Report*; 6 (1); 2018; 72-74;.
2. Ray S, Kundu S, Goswami M, Sarkar D, Saha M: Isolated tubercular splenic abscess: can we defer splenectomy? Our single experience with anti-tuberculous therapy alone. *Indian J Med Microbiol.* 2012, 30:101-103. 10.4103/0255-0857.93060;.
3. Metlo A, Shah S, Rehan A, et al. (July 23, 2019) Solitary Splenic Tuberculosis in an Im-

munocompetent Child: A Case Report. *Cureus* 11(7): e5210. doi:10.7759/cureus.5210;.

4. Lin SF, Zheng L, Zhou L: Solitary splenic tuberculosis: a case report and review of the literature. *World J Surg Oncol.* 2016, 14:154. 10.1186/s12957-016-0905-6;.
5. Mandal SK, Ganguly J et al; Isolated splenic tuberculosis in an immunocompetent patient- a case report; *BMJ Case Report* published online; doi: 10.1136/bcr-2013-203271;.
6. J.V. Basa et al.; A case report of isolated splenic tuberculosis; *International Journal of Surgery Case Reports*: 8 (2015): 117–119;.
7. Al-Naami MY.; An unusual presentation of tuberculosis splenic abscess; *Journal of Family & Community Medicine*; 1999; Jan- Jun; 6(1): 45-48;.

**How to cite this article:** D.T.S., Sundesha DNB Resident D.C., Gupta ,Senior Consultant Pediatrics D.D., Yadav, Senior Consultant Pediatrics D.M., Bhatia, Senior Consultant Radiology D.A., Sharma, Director and chief Radiologist D.N.K., Kumar, DNB Resident D.A. Tubercular Splenic Abscess with Gastrointestinal Tuberculosis in an Immunocompetent Child: A Rare Case Report. *Journal of Medical Case Reports and Reviews.* 2021;930–934. <https://doi.org/10.52845/JMCRR/2021/4-7-1>